

NOTE

Department of Medicine and Epidemiology and Center for Companion Animal Health, School of Veterinary Medicine, University of California, Davis, CA 95616, USA

'*Candidatus Mycoplasma haemominutum*', a low-virulence epierythrocytic parasite of cats

Janet E. Foley and Niels C. Pedersen

Author for correspondence: Janet E. Foley. Tel: +1 530 752 3692. Fax: +1 530 752 7701. e-mail: jefoley@ucdavis.edu

The phylogenetic position and some taxonomically relevant characteristics of a small, low-virulence bacterial parasite of cats are described. A 16S rDNA analysis revealed that the organism was in the *Mycoplasma* clade and was most closely related to a parasite of pigs previously designated *Eperythrozoon suis*. As the organism has not been cultured *in vitro* and is maintained in serial passage in cats *in vivo*, *Candidatus* status is proposed for this novel taxon as '*Candidatus Mycoplasma haemominutum*'.

Keywords: '*Candidatus Mycoplasma haemominutum*', feline infectious anaemia, *Haemobartonella felis*

Haemobartonellosis or feline infectious anaemia is a potentially fatal clinical syndrome of domestic cats consisting of immune-mediated osmotic fragility of erythrocytes following parasitism by the obligately epierythrocytic bacteria '*Candidatus Mycoplasma haemofelis*' (synonyms '*Eperythrozoon felis*', *Haemobartonella felis*). The causative organism is a 0.5–0.6 µm Gram-negative rod, coccus or disc-shaped parasite that replicates by binary fission. Both *Eperythrozoon* and *Haemobartonella* species were classed initially as rickettsias on the basis of staining characteristics, obligate parasitic habit, susceptibility to tetracycline and difficulty (or impossibility) of cultivation *in vitro*. Recently, we observed anaemia in a cat with no obvious '*Candidatus Mycoplasma haemofelis*' organisms on erythrocytes examined by Wright staining of thin blood smears. Through passage *in vivo*, it became clear that the cat was co-infected with an immunosuppressive feline leukaemia virus (FeLV) and a novel haemobartonella-like organism. Repeated passages *in vivo* consistently reproduced infection, although cats that were feline leukaemia-negative did not have haematological changes or clinical signs typical of moderate to severe haemobartonellosis. The new organism was described as *H. felis* small form (Hfsm), to distinguish it from the more common, larger Hflg. However, phylogenetic analysis and biological characteristics suggest that it may be a species distinct from '*Candidatus Mycoplasma haemofelis*'. We describe biological characteristics of this small feline haemoparasite and propose a candidate species name, '*Candidatus Mycoplasma haemominutum*'.

Morphological characteristics

Cells of '*Candidatus Mycoplasma haemominutum*' are approximately 0.3 µm in diameter, approximately half the size of '*Candidatus Mycoplasma haemofelis*' (Fig. 1). Cells of both species are Gram-positive, epicellular coccoid bodies. Ultrastructurally, '*Candidatus Mycoplasma haemominutum*' is similar to other mollicutes, with a plasma membrane, no cell wall and no internal membranous structures.

Clinical disease

Clinical signs in cats infected with '*Candidatus Mycoplasma haemominutum*' may be minor or absent and are not associated with fatality (Foley *et al.*, 1998). Likewise, haematological abnormalities are minor, if present. In one study, the mean packed cell volume (PCV) declined during the course of infection from 48.6 to 31.4%, but did not go below reference ranges (Foley *et al.*, 1998). Leukocyte counts also declined but stayed within reference ranges. '*Candidatus Mycoplasma haemominutum*' organisms were visible for 7–21 d, beginning on day 14 post-inoculation (p.i.), and were detected singly or occasionally multiply on each erythrocyte. In most cases, the date of maximal parasitism was the date of minimum PCV. Tetracycline abolished patent infections associated with '*Candidatus Mycoplasma haemominutum*' within 24 h and PCR tests became negative by 12 h after initiation of therapy (Foley *et al.*, 1998).

Following the acute stage of parasitaemia, cats may enter a series of infection cycles consisting of periods of latency and recrudescence (Foley *et al.*, 1998; Small & Ristic, 1987). Evidence of cycling was detected in four cats with '*Candidatus Mycoplasma haemominutum*'

Abbreviations: FeLV, feline leukaemia virus; FIV, feline immunodeficiency virus; PCV, packed cell volume.

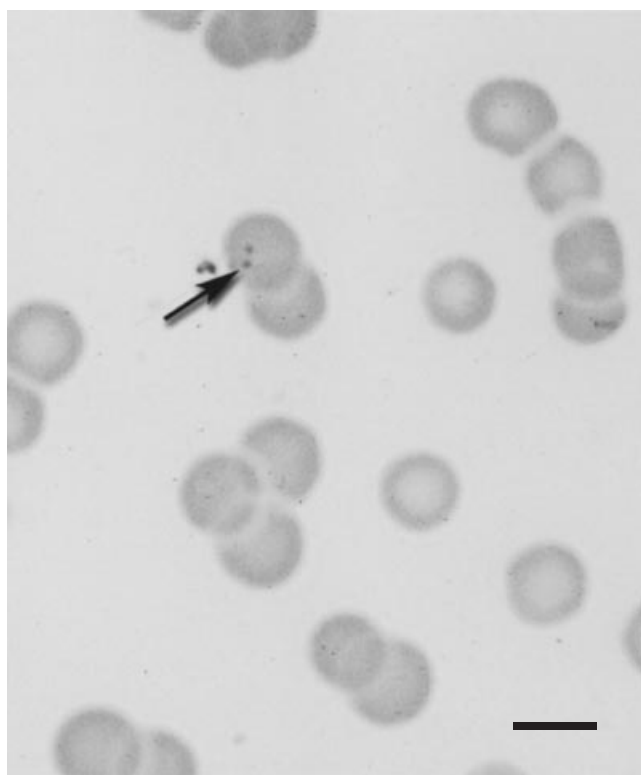


Fig. 1. 'Candidatus Mycoplasma haemominutum' organisms (arrow) on a Wright-Giemsa-stained feline blood smear. Bar, 6 μ m.

infections (Foley *et al.*, 1998; Small & Ristic, 1987). Cat #88506 had a reoccurrence of anaemia and depression 7 months after acute anaemia, with no clinical signs or haematological abnormalities during the intervening period. During the reactivated attack, the PCV declined from 44.9 to 21.3%. Approximately 5% of erythrocytes appeared to be parasitized by 'Candidatus Mycoplasma haemominutum' in the later attack.

Co-infection of 'Candidatus Mycoplasma haemominutum' with feline retroviruses has been evaluated (J. George and N. C. Pedersen, unpublished data). The cats with the most severe erythrocyte reductions were those infected with 'Candidatus Mycoplasma haemominutum' and feline leukaemia virus (FeLV), with or without feline immunodeficiency virus (FIV) infection. There was no mortality as a direct result of 'Candidatus Mycoplasma haemominutum' infection, but two cats in the FeLV-only group and one cat with FeLV and FIV developed myeloproliferative disorders characteristic of some end-stage FeLV infections during weeks 6 and 7.

Cats infected with 'Candidatus Mycoplasma haemominutum' develop IgG class antibodies that are somewhat cross-reactive with antibodies to 'Candidatus Mycoplasma haemofelis'. Experimentally infected cats were evaluated with an indirect immunofluorescent antibody assay using acetone-fixed whole-

blood smears from acutely infected cats as substrate (Foley *et al.*, 1998). Smears were coated with a 1:25 dilution of patient serum in PBS and incubated for 30 min at 37 °C with moisture. After washing, smears were coated with a 1:25 dilution of fluorescein-conjugated rabbit anti-cat IgG (Antibodies Inc.) and lightly counter-stained with Evans blue. Characteristic bright-green fluorescence was observed when 'Candidatus Mycoplasma haemominutum' substrate smears were reacted with 'Candidatus Mycoplasma haemominutum' sera but not 'Candidatus Mycoplasma haemofelis' sera. In contrast, 'Candidatus Mycoplasma haemofelis' smears reacted with both 'Candidatus Mycoplasma haemofelis' and 'Candidatus Mycoplasma haemominutum' sera. Seroconversion in cats infected with 'Candidatus Mycoplasma haemominutum' occurred in most cats by day 21 p.i., with a maximum titre of 400 by day 28 p.i. Infection with 'Candidatus Mycoplasma haemominutum' protected cats against challenge with the more virulent 'Candidatus Mycoplasma haemofelis' (Foley, 2001).

'Candidatus Mycoplasma haemominutum' has not been cultivated in artificial media; its entire existence is intimately associated with erythrocyte surfaces. Mycoplasmas in general require highly enriched media for growth. Unpublished unsuccessful culture protocols have included culture on mycoplasma media and on fresh cat blood agar. However, the type specimen is maintained frozen at the University of California, Davis, and the organism is propagated by *in vivo* passage in cats.

The epidemiology of 'Candidatus Mycoplasma haemominutum' infection is not known. Based on other feline haemobartonella-like organisms, the routes of infection may include *in utero* or lactogenic, iatrogenic, possibly oral and haematophagous arthropod transmission (Cretillat, 1984; Fisher, 1983; Harbutt, 1963; Harvey & Gaskin, 1977; Nash & Bobade, 1986; Splitter *et al.*, 1956).

PCR and genetic analysis

A PCR for 'Candidatus Mycoplasma haemominutum' and *M. haemofelis* was designed to amplify DNA extracted from feline whole blood using the QiaAmp tissue extraction kit (Qiagen) following the manufacturer's instructions (Foley *et al.*, 1998). Specific PCR primers are at position 1183 forward (5'-GCAT-AATGTGTCGCAATC-3') and 1290 reverse (5'-GTTTCAACTAGTACTTTCTCCC-3') of the 16S rRNA gene. 'Candidatus Mycoplasma haemominutum'/'Candidatus Mycoplasma haemofelis' PCR was performed using 20 pmol of each of these primers in 100 μ l containing final concentrations of 50 mM KCl, 10 mM Tris/HCl, 0.1% Triton X-100, 2.5 mM MgCl₂ and 0.2 mM each dNTP, 2 U *Taq* DNA polymerase and 60.6 μ l water. The cycling conditions were 94 °C for 4 min, followed by 35 cycles of 94 °C for 30 s, 53 °C for 1 min and 70 °C for 45 s, followed by a 5 min elongation step at 70 °C and cooling to 4 °C. The

positive band on ethidium bromide-stained, 1.5% agarose gels corresponded to a fragment of 130 bp. The 130 bp products were confirmed as ‘*Candidatus Mycoplasma haemominutum*’ amplicons by DNA sequencing. In ten cats with experimental ‘*Candidatus Mycoplasma haemominutum*’ infection, PCR tests were initially negative and became positive 8.8 d after inoculation on average. A published PCR protocol for 16S amplification of ‘*Candidatus Mycoplasma haemofelis*’ (Messick *et al.*, 1998) does not amplify ‘*Candidatus Mycoplasma haemominutum*’ DNA.

The 16S rRNA sequence of ‘*Candidatus Mycoplasma haemominutum*’ has been reported by Rikihisa *et al.* (1997) as the California strain of *H. felis*. The similarity between ‘*Candidatus Mycoplasma haemominutum*’ and ‘*Candidatus Mycoplasma haemofelis*’ is 83%. Analysis of the DNA sequence of the relatively conserved 16S rRNA gene revealed that ‘*Candidatus Mycoplasma haemominutum*’ is only distantly related to the rickettsias and should instead be placed in the family *Mycoplasmataceae*, an evolutionarily degenerate offshoot of the low-G+C-content Gram-positive bacteria (Foley *et al.*, 1998; Rikihisa *et al.*, 1997). ‘*Candidatus Mycoplasma haemominutum*’ is most closely related to *Eperythrozoon suis* (91% similarity) followed by *Mycoplasma muris* (79%) and other *Mycoplasma* species, while pathogenic ‘*Candidatus Mycoplasma haemofelis*’ strains from Ohio and Florida form a distinct clade with *Haemobartonella muris* (Foley *et al.*, 1998; Rikihisa *et al.*, 1997). This is surprising, given that mycoplasmas are typically mucosal pathogens. Other *Haemobartonella*-like organisms of man (Puntaric *et al.*, 1986), monkeys (Dillberger *et al.*, 1994) and dogs (Lester *et al.*, 1995) have not been sequenced but may be closely related to ‘*Candidatus Mycoplasma haemofelis*’ and ‘*Candidatus Mycoplasma haemominutum*’. As a result of recent phylogenetic analyses, a rearrangement of the genera *Mycoplasma*, *Haemobartonella* and *Eperythrozoon* has been proposed, in which all of these species are included in the genus *Mycoplasma* (Neimark *et al.*, 2001). The phylogenetic data suggest that the adaptation of epi- and intraerythrocytic parasitism has arisen independently several times (in the *Rickettsiaceae*, *Bartonellaceae* and *Mycoplasmataceae*) within the bacteria.

In accordance with guidelines for describing uncultivated prokaryotes (Murray & Stackebrandt, 1995), we propose giving this small feline parasite a *Candidatus* designation with the following description: ‘*Candidatus Mycoplasma haemominutum*’ [(Firmicute, probable *Mycoplasma*) NC; G+; C; NAS (GenBank no. U88564, U88563*); P (*Felis catus*, erythrocytes)]. Foley *et al.*, *Am J Vet Res* **59**, 1581–1588, 1998, and Rikihisa *et al.*, *J Clin Microbiol* **35**, 823–829, 1997.

Acknowledgements

We thank Jeff Carlson, Kim Floyd-Hawkins, Dr Robert Munn, Dr Dori Borjesson, Dr Patrick Foley, Dr Shimon

Harrus, Dr Jeanne George and Dr Harold Neimark. The research was supported by the School of Veterinary Medicine, Center for Companion Animal Health, George and Phyllis Miller Feline Foundation, the Krade and Maddox Endowments to UC Davis and the Winn Feline Foundation.

References

- Cretillat, S. (1984). Feline haemobartonellosis. *Feline Pract* **14**, 22–27.
- Dillberger, J. E., Loudy, D. E., Adler, R. R. & Gass, J. H. (1994). *Haemobartonella*-like parasites in cynomolgus monkeys (*Macaca fascicularis*). *Vet Pathol* **31**, 301–307.
- Fisher, E. (1983). Anemia in a litter of Siamese kittens. *J Small Anim Pract* **24**, 215–219.
- Foley, J. E. (2001). Feline hemobartonellosis. In *Consultations in Feline Internal Medicine*. Edited by J. R. August. Philadelphia: W. B. Saunders (in press).
- Foley, J. E., Harrus, S., Poland, A., Chomel, B. & Pedersen, N. C. (1998). Molecular, clinical, and pathologic comparison of two distinct strains of *Haemobartonella felis* in domestic cats. *Am J Vet Res* **59**, 1581–1588.
- Harbutt, P. (1963). A clinical appraisal of feline infectious anemia and its transmission under natural conditions. *Aust Vet J* **39**, 402–404.
- Harvey, J. & Gaskin, J. (1977). Experimental feline haemobartonellosis. *J Am Anim Hosp Assoc* **13**, 28–38.
- Lester, S. J., Hume, J. B. & Phipps, B. (1995). *Haemobartonella canis* infection following splenectomy and transfusion. *Can Vet J* **36**, 444–445.
- Messick, J. B., Berent, L. M. & Cooper, S. K. (1998). Development and evaluation of a PCR-based assay for detection of *Haemobartonella felis* in cats and differentiation of *H. felis* from related bacteria by restriction fragment length polymorphism analysis. *J Clin Microbiol* **36**, 462–466.
- Murray, R. & Stackebrandt, E. (1995). Taxonomic note: implementation of the provisional status *Candidatus* for incompletely described pathogens. *Int J Syst Bacteriol* **45**, 186–187.
- Nash, A. S. & Bobade, P. A. (1986). *Haemobartonella felis* infection in cats from the Glasgow area. *Vet Rec* **119**, 373–375.
- Neimark, H., Johansson, K.-E., Rikihisa, Y. & Tully, J. G. (2001). Proposal to transfer some members of the genera *Haemobartonella* and *Eperythrozoon* to the genus *Mycoplasma* with descriptions of ‘*Candidatus Mycoplasma haemofelis*’, ‘*Candidatus Mycoplasma haemomuris*’, ‘*Candidatus Mycoplasma haemosuis*’ and ‘*Candidatus Mycoplasma wenyonii*’. *Int J Syst Evol Microbiol* **51**, 891–899.
- Puntaric, V., Borcic, D., Vukelic, D., Jeren, T., Burek, V., Winkerhauser, T. & Richter, B. (1986). Eperythrozoonosis in man. *Lancet* *ii*, 868–869.
- Rikihisa, Y., Kawahara, M., Wen, B., Kociba, G., Fuerst, P., Kawamori, F., Suto, C., Shibata, S. & Futohashi, M. (1997). Western immunoblot analysis of *Haemobartonella muris* and comparison of 16S rRNA gene sequences of *H. muris*, *H. felis*, and *Eperythrozoon suis*. *J Clin Microbiol* **35**, 823–829.
- Small, E. & Ristic, M. (1987). Hemobartonellosis. In *Diseases of the Cat. Medicine and Surgery*, pp. 301–308. Edited by J. Holzworth. Philadelphia: W. B. Saunders.
- Splitter, E., Castro, E. & Kanawyer, W. (1956). Feline infectious anemia. *Vet Med Small Anim Clin* **51**, 17–22.