

SHORT ARTICLES

FATAL SALMONELLA SEPTICAEMIA WITH DISSEMINATED INTRAVASCULAR COAGULATION AND RENAL FAILURE

S. C. GLOVER, C. C. SMITH AND I. A. PORTER*

*Infection Unit and *Regional Laboratory, The City Hospital, Urquhart Road, Aberdeen AB2 1NJ*

SUMMARY. Four elderly patients with salmonella septicaemia complicated by irreversible endotoxic shock and acute renal failure are described. The organism isolated from three of the patients was *Salmonella typhimurium*, which is not usually invasive; the fourth patient was infected with *S. abony*. The factors associated with the severe systemic infections are discussed. Clinical and haematological findings suggested disseminated intravascular coagulation, and this was subsequently confirmed histologically in each patient by the identification of haematoxylinophil bodies in the pulmonary and renal microcirculations.

INTRODUCTION

Salmonella infection in man is worldwide and common, usually presenting as an acute diarrhoeal illness which may be complicated by septicaemia. In Britain, at the present time, classical enteric fever (caused by *Salmonella typhi* or *S. paratyphi* A, B or C) is occasionally encountered, although often acquired abroad. Infection by other salmonellae may cause typical infective diarrhoea, septicaemia, localised abscess formation or pyogenic arthritis. *S. typhimurium* is one of the commonest salmonellae to cause illness, but it rarely invades or causes fatal disease. Disseminated intravascular coagulation is an exceptional complication. The four elderly patients reported here all had severe invasive disease with similar clinical and pathological features.

CASE HISTORIES AND NECROPSY FINDINGS

Patient 1. A 76-year-old obese female was admitted to hospital with a 4-day history of persistent, non-bloody diarrhoea, latterly with vomiting. Before admission she had been given diphenoxylate hydrochloride with atropine sulphate (Lomotil) for 3 days without benefit. On examination she was drowsy, dehydrated, febrile, tachypnoeic and centrally cyanosed. Her abdomen was distended, with signs of peritonism. The blood pressure was 100/50 mm Hg and urine output was negligible. Black, blistered lesions, reminiscent of ecthyma gangrenosum, were present on the skin of the trunk, with more widespread ecchymoses. Laboratory investigations revealed a high and rising blood urea, a leucocyte count of $1.5 \times 10^9/L$, a platelet count of $70 \times 10^9/L$, a prolonged one-stage prothrombin time of 21 s (control 12), a prolonged activated partial thromboplastin time of 50 (control 37 s), and an elevated fibrin-degradation-product level, $> 40\text{mg/ml}$. She was treated with intravenous fluid replacement, ampicillin 500 mg 6-hourly by intravenous bolus injection and hydrocortisone 500 mg 6-hourly by intravenous infusion but remained oliguric, dying on the sixth day.

Salmonella abony, sensitive to ampicillin, tetracycline, chloramphenicol, carbenicillin, cotrimoxazole, gentamicin, cefuroxime and colistin, was grown from blood cultures, stools and sputum. At necropsy there was perforation of the distal jejunum into the mesentery. The kidneys were soft, with cortical pallor. Histological examination revealed haematoxylinophil bodies in the renal and pulmonary blood vessels, indicative of disseminated intravascular coagulation (figure, A and B).

Received 16 Feb. 1981; revised version accepted 5 Aug. 1981.

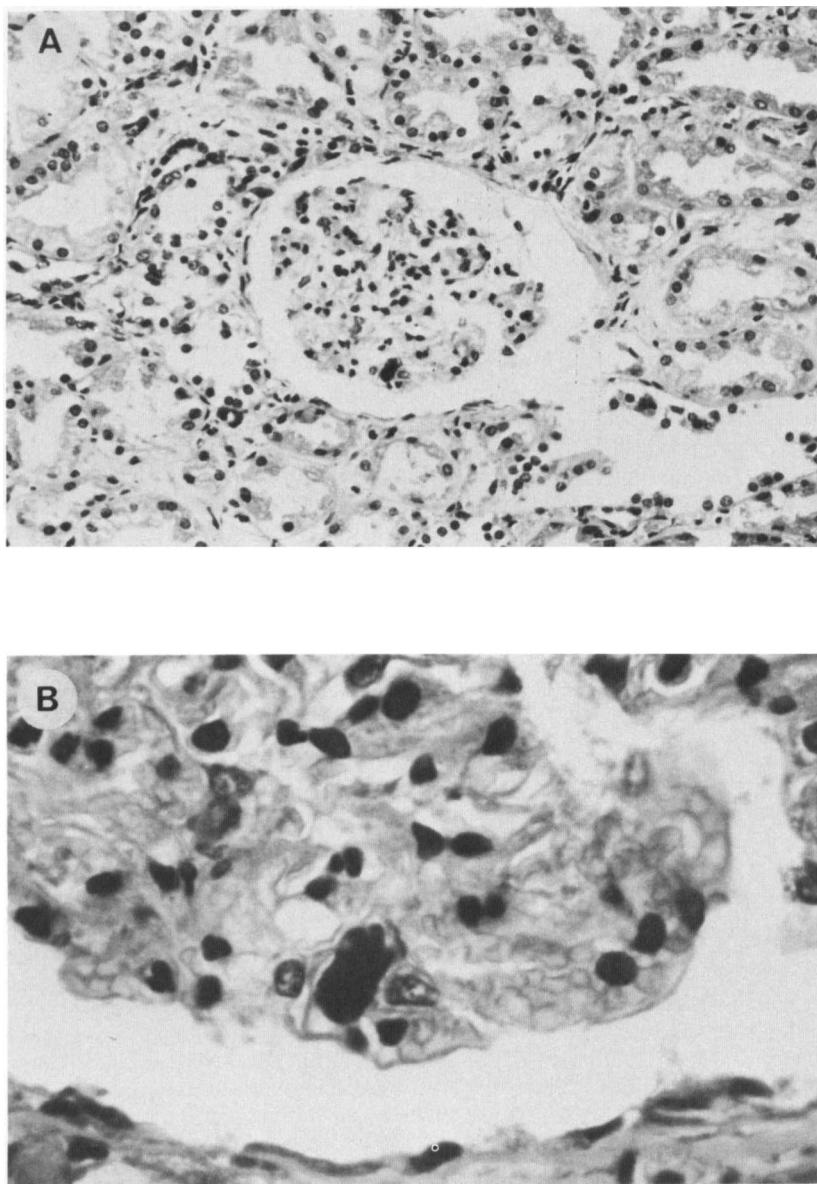


FIG. 1.—Dense haematoxylinophil bodies within the glomerular microcirculation. Haematoxylin and eosin. A, $\times 160$; B, $\times 400$.

Patient 2. A 65-year-old male, with a history of partial gastrectomy in 1959, was admitted with recurrent rigors, limb and joint pains, diarrhoea and abdominal pain for 2 weeks. Three days before his admission to hospital, his left arm went cold and his left thumb became painful and gangrenous. He was considered to be septicaemic but, despite treatment with cephaloridine 500 mg 8-hourly by bolus intravenous injection, his condition deteriorated with the development of tumid abdominal distension, intractable hypotension and oliguria. Laboratory investigation revealed a marked polymorphonuclear leucocytosis of $30 \times 10^9/L$, a high and rising blood urea, haematological evidence of disseminated intravascular coagulation with fragmented red blood

cells (schistocytes) in the blood film, platelet count $90 \times 10^9/L$, a prolonged one-stage prothrombin time of 31 s (control 12 s), a prolonged activated partial thromboplastin time of 54 s (control 39 s) and an elevated level of fibrin-degradation products, > 40 mg/ml. *Salmonella typhimurium*, phage type U268, was cultured from blood and stools; the antibiotic-sensitivity pattern is not now available. The parenteral antibiotic was changed to chloramphenicol 1.2 g intravenously every 6 h, but the patient remained oliguric and died on the seventh day after admission. At necropsy, the gastric mucosa was haemorrhagic and the small and large-bowel mucosal surfaces were superficially ulcerated. The kidneys showed marked cortical pallor. In the third part of the left subclavian artery was a 2-cm-long organised antemortem thrombus which occluded the lumen. Histological examination showed widespread fibrinous exudate in the alveoli, possibly due to shock lung, while the renal and pulmonary microvasculature contained haematoxylinophil bodies. The large-bowel mucosa was ulcerated and fibrin thrombi were seen in the blood vessels below these ulcerated areas. Fibrin thrombi were also seen in the intracranial vessels, indicating widespread intravascular coagulation.

Patient 3. A 68-year-old female was admitted with a 1-week history of nausea, diarrhoea, and abdominal and back pain. These symptoms had not responded to diphenoxylate hydrochloride, with atropine sulphate (Lomotil) or metoclopramide hydrochloride (Maxolon) given for 4 days. Examination revealed an obese, tachypnoeic, cyanosed, dehydrated woman with a racing tachycardia and an unrecordable blood pressure. There were widespread ecchymoses. Her abdomen was distended with tenderness in the left iliac fossa and signs of peritonism. Investigations revealed a profound acidaemia, uraemia, a polymorphonuclear leucocytosis of $19 \times 10^9/L$, schistocytes in the blood film, a platelet count of $50 \times 10^9/L$, a prolonged one-stage prothrombin time of 27 s (control 13 s), a prolonged activated partial thromboplastin time of 49 s (control 36 s) and elevated serum levels of fibrin-degradation products, > 40 mg/ml. She was treated with intravenous fluids, hydrocortisone 500 mg intravenously every 6 h, high airflow oxygen, and cefoxitin 2-g loading dose by bolus intravenous injection. Despite these measures she remained anuric and hypotensive, dying 18 h after admission. At necropsy a necrotic segment of ileum was noted. The kidneys were small with pale thir cortices. *Salmonella typhimurium*, phage type 8, sensitive to gentamicin, cotrimoxazole, ampicillin, chloramphenicol and cefoxitin but resistant to tetracycline and sulphafurazole, was cultivated from blood taken at the time of admission to hospital and from small and large-bowel contents, gall bladder and splenic pulp obtained at necropsy. Haematoxylinophil bodies were identified in the renal and pulmonary blood vessels.

Patient 4. A 71-year-old male, with a history of gastroenterostomy and obstructive uropathy, developed acute diarrhoea and vomiting while on holiday in Spain. He had been treated with metoclopramide hydrochloride (Maxolon) and a non-absorbable oral sulphonamide for 3 days. On admission to hospital he was ill, dehydrated and febrile. His abdomen was distended and the bowel sounds were infrequent. Investigations showed a high and rising blood urea, a polymorphonuclear leucocytosis of $21.5 \times 10^9/L$, a platelet count which fell from $128 \times 10^9/L$ to $27 \times 10^9/L$ and schistocytes in the blood film. The one-stage prothrombin time was 28 s (control 13 s), the activated partial thromboplastin time was 53 s (control 41 s) and the serum fibrin-degradation products > 40 mg/ml. He was initially treated with ampicillin, 500 mg 6-hourly by intravenous bolus injection, and was rehydrated with intravenous fluids. On the third day after admission he became stuporose, dyspnoeic and hypotensive with clinical and radiographic evidence of bronchopulmonary infection. *Salmonella typhimurium*, phage type 193, was isolated from the initial blood cultures; it was sensitive to ampicillin, gentamicin, chloramphenicol and cotrimoxazole but resistant to tetracycline, neomycin, streptomycin and sulphafurazole. At this stage the antimicrobial therapy was changed to chloramphenicol 500 mg 6-hourly by intravenous bolus injection. Despite the change of therapy he continued to deteriorate, became anuric and died on his fifth day in hospital. Necropsy revealed a confluent bronchopneumonia, bilateral adrenal haemorrhages, thinning of the large bowel wall and right-sided hydronephrosis. Histological examination demonstrated haematoxylinophil bodies in the renal and pulmonary microcirculations.

DISCUSSION

These four elderly patients were admitted to the Aberdeen Infection Unit with persistent

diarrhoea. A presumptive diagnosis of infective diarrhoea was made on three of them; the fourth (patient 3) was thought to have ischaemic colitis or diverticulitis with septicæmic shock. The patients were hypotensive, dehydrated and febrile on admission, remained oliguric despite adequate intravenous fluid replacement, and died within a week of admission to hospital. *Salmonella* was isolated from stool and blood cultures from each patient. Treatment with antimicrobial and supportive therapy was started after blood cultures were taken, but each patient developed clinical and haematological evidence of disseminated intravascular coagulation as described above, with widespread cutaneous ecchymoses in two patients.

Necropsy showed histopathological evidence of disseminated intravascular coagulation in each case, with deposition of fibrin within the microcirculation and the presence of haematoxylinophil bodies in the renal and pulmonary microcirculations and evidence of organ damage elsewhere. Haematoxylinophil bodies are composed of condensed nuclear material extruded from vascular endothelial cells after intravascular coagulation and fibrin deposition, and are characteristic of this condition. They are seen at the sites of intravascular coagulation and embolise to renal and pulmonary capillaries. Their association with fibrin in the microcirculation is strong evidence of disseminated intravascular coagulation, whatever the stimulus (Hamilton, Stalker and Douglas, 1978).

Bacteraemic shock occurs when bacterial toxins are released into the circulation. Gram-negative bacteria, such as the Enterobacteriaceae and *Pseudomonas aeruginosa* are the major precipitants of the endotoxic and septic-shock syndromes, but septic shock can also arise with gram-positive bacteraemia, for example with *Streptococcus pneumoniae*, *Str. pyogenes* or *Staphylococcus aureus* (Smith and Murdoch, 1976). During severe gram-positive infections about one patient in 10 becomes shocked at some stage, compared with one in three during gram-negative infections. The latter also carry a significantly higher incidence of disseminated intravascular coagulation and are associated with a 60% mortality, even with treatment (Dr S. Eykyn and Professor I. Phillips, personal communication). Similar figures have been produced from the USA and show that 49–56% of bacteraemias studied were caused by enterobacteriaceae and *P. aeruginosa*, with a mortality of 30–50% (Mandell, Douglas and Bennett, 1979).

Endotoxin is a complex lipopolysaccharide which is present in the outer cell membrane of all gram-negative bacteria, including *Salmonella* spp. Within the lipopolysaccharide outer membrane is lipid A, which is thought to be the major component of endotoxin that is involved in the precipitation of the coagulation cascade. Freely circulating endotoxin will activate several biological systems in addition to the coagulation and fibrinolytic systems, releasing complement, kinins, prostaglandins and histamine, causing vasoconstriction and vascular endothelial damage (Westphal, 1975). Disseminated intravascular coagulation is produced during endotoxaemia by a combination of vasoconstriction, platelet damage, vascular endothelial damage and inhibition of local fibrinolysis. Hageman factor (factor XII) triggers the cascade of intrinsic coagulation, causing widespread intravascular deposition of fibrin; microthrombus formation is followed by tissue ischaemia and organ dysfunction and then breakdown of the fibrin by fibrinolysis (Smith and Murdoch, 1976).

The observation that disseminated intravascular coagulation can occur in severe septicaemic salmonellosis prompts the question of its prevention and treatment. Specific antimicrobial therapy and resuscitative fluid therapy are essential. The use of heparin is potentially dangerous, and the indications for its use, the timing and the dosage, are speculative (Sharp, 1977). None of our patients received heparin.

Death from salmonella infection is now uncommon in Britain. In 1977 and 1978, the Communicable Disease Surveillance Centre, Colindale, recorded 19 041 salmonella isolates from man of whom 93 (0.5%) died (Public Health Laboratory Service, 1979). Also reported were 311 salmonella isolates from extra-intestinal sites, associated with 53 (17%) deaths. Allowing for some inaccuracy of reporting, it nevertheless appears that extra-intestinal salmonella infection, while it accounted for only 1.7% of all reported isolates, was associated with 57% of the deaths associated with these. There is no evidence that any particular salmonella serotype is especially liable to produce extra-intestinal infection, but the isolation of a salmonella from an extra-intestinal site is suggestive of a more severe infection and may indicate an underlying impairment of host defences.

Several host factors are known to influence the severity of salmonella infections. These

adverse factors include the extremes of age, achlorhydria (Gray and Trueman, 1971), previous gastric resection (Waddell and Kunz, 1956), co-existent diseases, chronic haemolytic disease (Hook, Kaye and Gill, 1967), other debilitating disease (Mandell, Douglas and Bennett, 1979), immunosuppressive therapy (Hook, 1961) and possibly therapy with antacids, oral antibiotics, and intestinal sedatives. Previous therapy with oral streptomycin markedly reduces the size of the infecting dose required to produce salmonella infections in animals (Miller and Bohnhoff, 1963). Medications that alter small-bowel mobility, such as metoclopramide hydrochloride (Maxolon) and diphenoxylate hydrochloride with atropine sulphate (Lomotil) have been shown to have an adverse effect on the clinical course of acute shigellosis, but these observations have not yet been extended to salmonella infections (Dupont and Hornick, 1973). Of our four patients, three had taken drugs with known actions on gastrointestinal motility, two had previously undergone gastric resection and one had taken a non-absorbable oral sulphonamide. Patient 4 demonstrated four separate factors thought to be associated with more severe salmonella infection. It is well known that *S. typhi* and *paratyphi* cause a bacteraemic illness occasionally complicated by disseminated intravascular coagulation (Smith and Murdoch, 1976; Butler, Bell and Levin, 1978) but *S. typhimurium* and *S. abony* rarely do so. We believe that our four patients with fatal salmonella septicaemia developed irreversible endotoxic shock with disseminated intravascular coagulation because of the predisposing host factors described.

We thank Professor A. L. Stalker, Department of Pathology, University of Aberdeen, and his staff for the necropsy details. In particular, we acknowledge the help and advice of Dr S. W. B. Ewen, who interpreted the histopathological specimens and prepared the photomicrographs. We also thank Dr Susan Young, CDSC, Colindale, for helpful advice and permission to quote figures derived from records of salmonella isolates notified to the Public Health Laboratory Service.

REFERENCES

- BUTLER, T., BELL, W. R., LEVIN J., LINH, N. N. AND ARNOLD, K. 1978. Typhoid fever: studies of blood coagulations, bacteraemia and endotoxaemia. *Archs intern. Med.*, **138**, 407.
- DUPONT, H. L. AND HORNICK, R. B. 1973. Adverse effect of Lomotil therapy in shigellosis. *J. Am. med. Ass.*, **226**, 1525.
- GRAY, J. A. AND TRUEMAN, A. M. 1971. Severe salmonella gastroenteritis associated with hypochlorhydria. *Scott. med. J.*, **16**, 255.
- HAMILTON, P. J., STALKER, A. L. AND DOUGLAS A. S. 1978. Disseminated intravascular coagulation—a review. *J. clin. Path.*, **31**, 609.
- HOOK, E. W. 1961. Salmonellosis: certain factors influencing the interaction of salmonella and the human host. *Bull. N.Y. Acad. Med.*, **37**, 499.
- HOOK, E. W., KAYE, D. AND GILL F. A. 1967. Factors influencing host resistance to salmonella infection. The effects of hemolysis and erythrophagocytosis. *Trans. Am. clin. climat. Ass.*, **78**, 230.
- MANDELL, G. L., DOUGLAS R. G. AND BENNETT, J. E. 1979. Principles and practice of infectious diseases. John Wiley & Sons, New York, pp. 572 and 1730–1750.
- MILLER C. P. AND BOHNHOFF, M. 1963. Changes in the mouse's enteric microflora associated with enhanced susceptibility to *Salmonella* infection following streptomycin treatment. *J. infect. Dis.*, **113**, 59.
- PUBLIC HEALTH LABORATORY SERVICE. 1979. Extra-intestinal salmonella infections reported to CDSC 1977–1978. Communicable Disease Report no. 26.
- SHARP A. A. 1977. Diagnosis and management of disseminated intravascular coagulation. *Br. med. Bull.*, **33**, 265.
- SMITH C. C. AND MURDOCH, J. MCC. 1976. Infection. In Haematological aspects of systemic disease, edited by M.G.C. Israels and I.W. Delamore, Saunders, Philadelphia, pp. 342–370.
- WADDELL, W. R. AND KUNZ L. J. 1956. Association of salmonella enteritis with operations on the stomach. *N. Engl. J. Med.*, **255**, 555.
- WESTPHAL, O. 1975. Bacterial endotoxins. *Int. Archs Allergy appl. immun.*, **49**, 1.