

VIROLOGY

Investigation of the simian polyomavirus SV40 as a potential causative agent of human neurological disorders in AIDS patients

M. TOGNON*†, F. MARTINI*†, L. IACCHERI*†, R. CULTRERA‡ and C. CONTINI‡

*Department of Morphology and Embryology, Section of Histology and Embryology, †Centre of Biotechnology and ‡Department of Clinical and Experimental Medicine, Section of Infectious Diseases, University of Ferrara, 44100 Ferrara, Italy

Neurological diseases and a variety of neoplasms frequently occur in AIDS patients. Human JC and BK polyomaviruses have been associated with neurological disorders in such patients. SV40 polyomavirus sequences have been detected in human brain tumours, other neoplasms and normal tissues. JCV, BKV and SV40 DNA sequences were investigated in cerebrospinal fluid (CSF) samples from 12 AIDS patients affected by different neurological disorders, by PCR assay and filter hybridisation with specific internal oligoprobes, and DNA sequencing. Three of the 12 CSF samples were positive for JCV (one sample) or SV40 (one) DNA, or both (one). No sample was positive for BKV DNA. JCV- and SV40-specific genomic regions were confirmed by DNA sequencing. CSF samples from the two patients diagnosed clinically as having progressive multifocal leukoencephalopathy (PML) contained either JCV (one sample) or SV40 (one) DNA. The CSF found to contain both JCV and SV40 DNA originated from a patient with a cerebral mass lesion of unknown aetiology. These results suggest that SV40 may be involved in the aetiology of PML in AIDS patients, and raise the possibility that SV40 and JCV may act synergically *in vivo* to enhance their pathogenicity.

Introduction

Superinfections with opportunist agents, including fungi, protozoa, bacteria and viruses, occur in the central nervous system (CNS) of patients affected by the acquired immunodeficiency syndrome (AIDS) [1]. It is well established that most of these superinfections can cause neurological diseases [2]. Progressive multifocal leukoencephalopathy (PML) is a rare demyelinating disease of the CNS, the occurrence of which is dramatically increased in AIDS patients, accounting for up to 10% of deaths [3], although the recent introduction of highly active antiretroviral therapy (HAART) has reduced the number of PML cases reported in HIV-infected patients. HIV-encephalopathy, apparently caused by HIV-1 itself [4], is also prevalent in AIDS patients [4, 5]. About 40% of AIDS patients develop specific tumours of different histological types [6].

These neoplasms arise mostly due to impairment of the patients' immune system and the presence of latent viral agents [6, 7]. Other neurological manifestations and intracranial neoplasms affecting AIDS patients are not well classified and aetiological agents remain to be completely determined [6, 8].

The oncogenic and neurotropic JC, BK and simian virus 40 (SV40) polyomaviruses are associated with neurological diseases and human tumours [9, 10]. Human JCV is the causative agent of PML [11], and JCV DNA sequences and its large T antigen (Tag) oncoprotein have been detected in human medulloblastomas [12]. BKV is associated with diseases of immunocompromised patients, and has been detected in the brain and cerebrospinal fluid (CSF) of an AIDS patient with meningo-encephalitis [13]. BKV sequences were also detected in neuroblastomas [14], other human tumours and normal tissues [15]. SV40 sequences have been detected by PCR and Southern blot hybridisation in human brain [16, 17] and bone tumours of different histological types [18, 19], pleural mesotheliomas [20], papillary thyroid tumours [21], pituitary adenomas [22] and in different lymphoproliferative disorders [23].

Received 28 April 2000; revised version received 29 June 2000; accepted 8 July 2000.

Corresponding author: Dr M. Tognon (e-mail: tgm@dns.unife.it).

SV40 wild-type was isolated from a child affected by anatomical and neurological anomalies [24], from a glioblastoma multiforme sample [25] and from PML cases [26–28]. SV40 isolates from PML have been questioned recently [29, 30] but the ability of SV40 to infect man is well documented [9, 10, 20, 23]. SV40 DNA sequences have been detected by PCR in normal tissues [9, 10, 17, 19], and SV40-neutralising antibodies have been detected in both HIV-negative (11%) and HIV-positive (16%) individuals [31].

SV40 is the causative agent of PML in macaques [32]; it induces PML in macaques affected by malignant diseases or chronic infections, with a relatively low incidence [33]. However, macaques with SIV-induced AIDS are highly predisposed to primary and recrudescence polyomaviral diseases [34]. Moreover, SV40 can cause meningo-encephalitis in SIV-infected macaques [35].

In this study, SV40, JCV and BKV sequences were investigated, retrospectively, by PCR of DNA extracted from CSF samples of 12 AIDS patients affected by different neurological disorders. None of these patients had received protease inhibitors or HAART at the time of sample collection. The specificity of the PCR amplified products was assessed by filter hybridisation with specific internal oligoprobes for JCV, BKV and SV40 genomes, and DNA sequencing.

Materials and methods

Patients and specimens

CSF specimens from 12 AIDS patients were obtained from the Department of Infectious and Tropical Diseases, University of Rome 'La Sapienza'. Patients had undergone lumbar puncture (LP), under sterile conditions, for assessment of neurological dysfunction. LP was performed after obtaining written consent from

all patients and approval by the regional committee for medical ethics in research. Data on demographic characteristics, clinical presentation, HIV status, HIV risk behaviours and CSF laboratory results for each case were obtained from hospital records. Four patients had toxoplasma encephalitis (TE, Table 1) diagnosed according to the Centers for Disease Control and Prevention (CDC) guidelines on the basis of: (i) focal or generalised neurological symptoms; (ii) single or multiple contrast-enhancing brain lesions detected by computerised tomography (CT) or magnetic resonance imaging (MRI) scans, or both; (iii) positive *Toxoplasma gondii* serology or positive PCR assay, or both [36]; (iv) CSF negative for Epstein-Barr virus (EBV) DNA; (v) positive response to standard pyrimethamine and sulphadiazine therapies. None of the four subjects with TE had concomitant CNS opportunist diseases. The remaining eight patients presented with clinical signs of neurological disorders, supporting a diagnosis of encephalitis or intracranial mass lesions. Aetiologies considered to be responsible for these disorders included PML (n = 2), EBV-associated primary CNS lymphoma (1), HCMV encephalitis (1), HIV-related dementia (1), cerebral cryptococcosis (1), presumptive TE (1) and cerebral bacterial abscess (1) (Table 1). In six of these patients, the clinical diagnosis was subsequently confirmed at post mortem examination (Table 1). For two patients (diagnosed as PML and presumptive TE), no permission for post mortem examination was obtained from parents or relatives. Of particular interest, confirmation of one of the diagnoses of PML was obtained by in-situ hybridisation with a biotin-labelled DNA probe (Diagnostic Systems, NY, USA) for JCV DNA.

Nucleic acid purification

Portions of CSF samples from the 12 AIDS patients were kept at -80°C . DNA was extracted as described

Table 1. Summary of PCR and filter hybridisation analyses performed with DNA from CSF samples of 12 AIDS patients affected by different neurological disorders

DNA samples	SV40				JCV		Clinical diagnosis
	Tag-N-terminal region	Tag-C-terminal region	Regulatory region	VP1 region	Tag-N-terminal region	Regulatory region	
13	–	–	–	–	–	–	TE
16	–	–	–	–	–	–	HCMV encephalitis*
22	–	–	–	–	–	–	TE
23	–	–	–	–	–	–	TE
25	–	–	–	–	–	–	CNS lymphoma* EBV+
34	–	–	–	–	–	–	TE
37	–	–	–	–	–	–	HIV-related dementia*
41	+	–	–	–	–	–	PML
43	–	–	–	–	+	–	PML*
48	–	–	–	–	–	–	Cerebral cryptococcosis*
50	+	+	–	+	+	+	Cerebral mass lesion (presumptive TE)
59	–	–	–	–	–	–	Cerebral bacterial abscess*

TE, toxoplasma encephalitis, diagnosed according to CDC guidelines.

*Clinical diagnosis confirmed at post mortem.

previously [36]. To verify whether cross-contaminations occurred during DNA extraction procedures, salmon sperm DNA and mock specimens lacking DNA were extracted simultaneously with the samples under analysis in a 1:1 ratio.

PCR and filter hybridisation

DNA extracted from samples was first assessed for suitability for PCR analysis by a control reaction designed to amplify β -globin gene sequences, as described previously [17]. The samples were then investigated for JCV, BKV and SV40 DNA sequences. To reduce the risk of PCR contamination, the distinct phases of the PCR procedures were performed in separate rooms by different operators at the Section of Histology and Embryology and Centre for Biotechnology, University of Ferrara. JCV-Mad-1, BKV-Dunlop and SV40-776 wild-type strains, cloned in plasmid vectors, were used as positive controls (100 ng each). Samples were investigated by PCR (35 cycles), followed by filter hybridisation with specific internal oligoprobes, for JCV and BKV Tag-amino (N)-terminal and regulatory regions, and for SV40 Tag-N- and carboxyl (C)-terminal, regulatory and VP1 regions. Oligonucleotides employed in the PCR and filter hybridisations, annealing temperatures and product sizes are summarised in Table 2. PYV.for and PYV.rev primers amplify a conserved region of the Tag gene of JC, BK and SV40 viruses (Table 2). Probes specific for each virus (JC-, BKV- and SV-labelled oligoprobes which do not cross-hybridise) [16, 17, 23] were used to discriminate among the amplified viral sequences. JCV and BKV regulatory regions were investigated with J3

and J4 primers, which amplify PCR products of 718 bp and 686 bp, respectively [37]. SV40 Tag-C-terminal region was investigated with TA1 and TA2 primers, which amplify a PCR product of 441 bp, followed by filter hybridisation with the internal T probe [37]. SV40 regulatory region was studied by PCR with RA1-RA2 (314 bp) [37] and filter hybridisation with the R probe. SV40 VP1 late region was searched with the LA1-LA2 (294 bp) [37] primers and filter hybridised with the L probe [37] (Table 2). DNA (0.5 μ g) was amplified in a total volume of 50 μ l containing 10 mM Tris-HCl, pH 8.3, 50 mM KCl, 1.5 mM MgCl₂, gelatine 0.01%, 150 μ M of each dNTP, 25 picomoles of each primer and 1 unit of Taq polymerase linked to its specific antibody (Life Technologies-Gibco BRL). PCR products were electrophoresed in agarose gels (1–2%), stained by ethidium bromide and transferred to a nylon membrane. DNA was cross-linked to filters by UV irradiation for 2 min. Specific internal oligoprobes were 3' end-labelled with a tail of dUTP-fluorescein by terminal transferase, as recommended by the manufacturer (Amersham). The fluorescent hybrid was detected with anti-fluorescein horseradish peroxidase-conjugated antibody, as indicated by the supplier (Amersham). Autoradiography was carried out at room temperature for 15–60 min.

DNA sequencing

PCR amplified fragments were sequenced directly [17]. Briefly, 40 μ l of the PCR amplified products were purified from agarose gels with a commercial kit (Boehringer). DNA sequence analysis was performed

Table 2. Oligonucleotides used in PCR and filter hybridisation

Region	Oligonucleotides	Reference positions	T	Size (bp)
JCV: NH ₂ Tag region	PYV.for: 5'-TAGGTGCCAACCTATGGAACAGA-3'	nt 4429–4407*	54	178
	PYV.rev: 5'-GAAAGTCTTTAGGGTCTTCTACC-3'	nt 4252–4274*		
	JC probe: 5'-GTTGGGATCCTGTGTTTTTCAT-3'	nt 4303–4323*		
Regulatory region	J3: 5'-CATGAGCTCCATGGATTCTCC-3'	nt 4972–4992*	60	718
	J4: 5'-CTAGGTCCCCAAAAGTGCTAG-3'	nt 559–538*		
BKV: NH ₂ Tag region	PYV.for: 5'-TAGGTGCCAACCTATGGAACAGA-3'	nt 4569–4547†	54	181
	PYV.rev: 5'-GAAAGTCTTTAGGGTCTTCTACC-3'	nt 4389–4411†		
	BKV probe: 5'-AATCTTCATCCATTTTTCA-3'	nt 4497–4516†		
Regulatory region	J3: 5'-CATGAGCTCCATGGATTCTCC-3'	nt 5112–5133†	60	686
	J4: 5'-CTAGGTCCCCAAAAGTGCTAG-3'	nt 656–636†		
SV40: NH ₂ Tag region	PYV.for: 5'-TAGGTGCCAACCTATGGAACAGA-3'	nt 4574–4552‡	54	172
	PYV.rev: 5'-GAAAGTCTTTAGGGTCTTCTACC-3'	nt 4403–4425‡		
	SV probe: 5'-ATGTTGAGAGTCAGCAGTAGCC-3'	nt 4452–4473‡		
COOH Tag region	TA1: 5'-GACCTGTGGCTGAGTTGCTCA-3'	nt 3070–3048‡	60	441
	TA2: 5'-GCTTTATTTGTAACCATTATAAG-3'	nt 2630–2652‡		
Regulatory region	T probe: 5'-AACCTTACAAATGTGGTATGGCT-3'	nt 2741–2764‡	55	314
	RA1: 5'-AATGTGTGTGTCAGTTAGGGTGTG-3'	nt 266–245‡		
	RA2: 5'-TCCAAAAAGCCTCTACTACT-3'	nt 5195–5218‡		
	R probe: 5'-TTAGTCAGCCATGGGGCGGAGA-3'	nt 29–50		
	LA1: 5'-GGGTGTTGGGCCCTTGTGCAAAGC-3'	nt 2251–2274‡		
VP1 region	LA2: 5'-CATGTCTGGATCCCCAGGAAGCTC-3'	nt 2545–2522‡	60	294
	L probe: 5'-TTAACAGGAGGACACAGAGGGTGGATGG-3'	nt 2433–2460‡		

T, PCR annealing temperature (°C).

*Reference nucleotide (nt) positions in JCV reference strain Mad-1 (pJCV-Mad-1).

†pBKV (Dunlop strain).

‡SV40 reference strain 776 (pSV40-776).

with the Sequenase kit, version 2.0 (USB Amersham Pharmacia).

Results

PCR analysis

Twelve CSF samples from AIDS patients affected by neurological disorders were tested for JCV, BKV and SV40 DNA sequences. One CSF sample, from patient 50 who had a cerebral mass lesion of undetermined origin, was positive for the SV40 Tag-N- and -C-terminals and VP1 late regions (Fig. 1a, b and c), and for the JCV Tag-N-terminal and regulatory sequences (Fig. 1a and d). Two CSF samples, from cases 41 and 43, were positive for the SV40 and JCV Tag-N-terminal sequences (Fig. 1a), respectively (Table 1). None of the 12 CSF samples contained BKV sequences (Fig. 1a).

DNA sequence analysis of amplified products

To assess the specificity of the SV40 and JCV sequences detected by PCR and filter hybridisation, amplified products from samples 41, 43 and 50 were directly sequenced. DNA sequence analysis showed that the PCR products corresponded to SV40 and JCV sequences. SV40 amplified products did not show any DNA variability or mutations compared to SV40 wild-type, whereas the JCV regulatory sequences, detected in CSF sample 50, differed from the regulatory region of the JCV Mad-1 strain, used as control. Sample 50 exhibited DNA sequences closely related to the JCV archetype strain [38] with two large deletions from nucleotide 156–178 (23 bp) and from nucleotide 206–224 (19 bp). This sample also showed three point mutations at nucleotide 108 (G–A transition), nucleotide 152 (T–A transversion) and nucleotide 154 (A–G transition) (Fig. 2).

Clinical synopsis

Patient 41 was a 34-year-old heterosexual male, with a history of intravenous drug use, diagnosed as HIV-infected in 1992. He had had no other AIDS-defining illness previously and was naive to antiretroviral therapy. He was admitted in April 1994 for evaluation of a left-sided hemiparesis. He had no history of fever, seizure activity or headache. Examination revealed severe hypotonic upper and lower extremity weakness and general hypotonia. Analysis of a CSF sample showed pleocytosis, with increased protein and glucose concentration. At this time his CD4+ cell count was $<50/\mu\text{l}$. A CT scan showed hypodense lesions without mass effect and enhancement in the right occipital and parietal regions with neurological evidence of white matter disease, while a plain contrast-enhanced MRI of the brain exhibited signal modification highly suggestive of PML with no evidence of enhancement or mass effect. A preliminary diagnosis of PML was based on

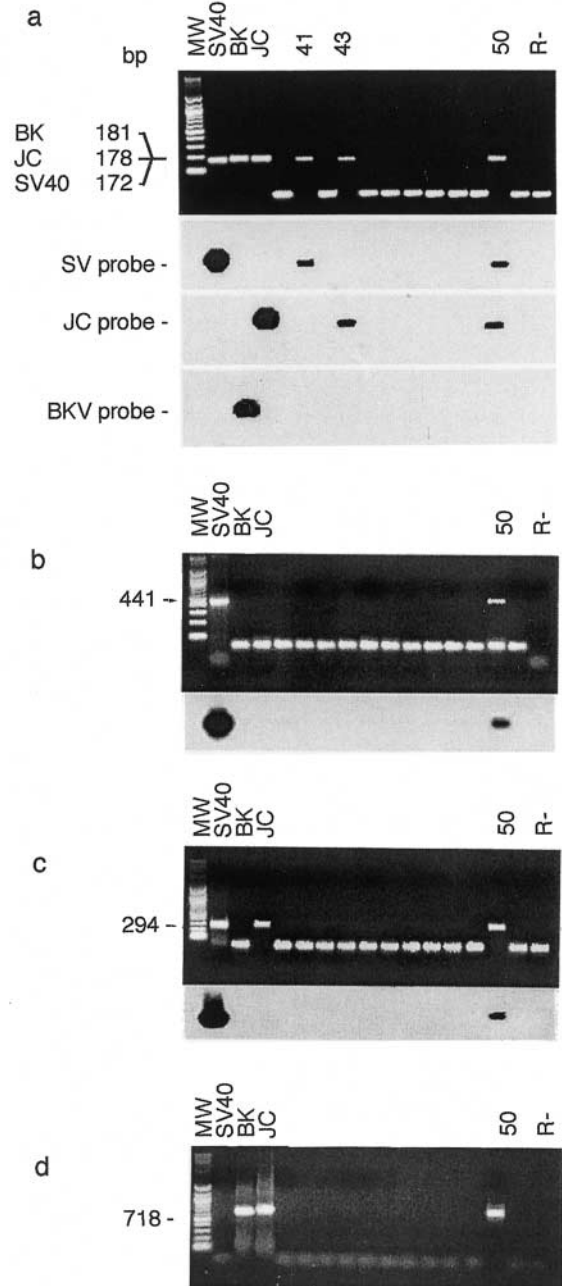


Fig. 1. Agarose gel electrophoresis stained by ethidium bromide and autoradiographic images of DNA from 12 CSF specimens analysed by PCR and filter hybridisation. Lanes: MW, mol. wt markers (100-bp ladder); SV40, BK and JC, PCR positive controls from recombinant plasmids; R-, negative control of the PCR reaction without DNA template. (a) Top panel: PCR for the polyomavirus Tag-N-terminal sequences. Arrows indicate the PCR product size of the BKV (181 bp), JCV (178) and SV40 (172) Tag-N-terminal sequences. Bottom panels: autoradiographic images of PCR-amplified products hybridised to the internal SV, JC and BKV probes. (b) Top panel: PCR for the SV40 Tag-C-terminal region; arrow indicates the 441-bp PCR product size. Bottom panel: autoradiographic image of PCR-amplified DNA hybridised to the SV40 specific internal T probe. (c) Top panel: PCR for the SV40 VP1 region; arrow indicates the 294-bp PCR product size. Bottom panel: autoradiographic image of PCR-amplified DNA hybridised to the SV40 specific internal L probe. (d) PCR for the JCV regulatory region; arrow indicates the 718-bp PCR product size of JCV Mad-1 strain.



Fig. 2. Alignment of JCV Mad-1 strain (middle) and CSF sample 50 (bottom) DNA sequences with archetype sequence (top) between the origin of replication (at nucleotide 1 in genome map) and the late ATG codon. Full lines indicate identity with the archetype sequence, gaps are deletions relative to archetype, repeats begin on the next line. Nucleotide substitutions in sample 50, compared with archetype sequence, are indicated with capital letters.

the typical MRI appearance, negative serology and PCR assay for *T. gondii*, and a negative cryptococcal antigen test. PCR assays on CSF for JCV, HCMV and EBV DNA were negative. The patient received intravenous cytarabine (Ara-C) at 2 mg/kg daily for 5 consecutive days. Cycles were repeated with intervals of 2 weeks between each 5-day treatment. Zidovudine was also given (1000 mg/day) and granulocyte colony-stimulating factor (G-CSF, 3 mg/kg subcutaneously) was administered to reduce the risk of neutropenia. Other medications included dexamethazone, mannitol and clarithromycin. Four days after administration, the Ara-C cycle was interrupted because of fever, nausea and vomiting. In May 1994, the patient's condition began to deteriorate with mental derangement, global cognitive impairment, impaired memory and seizures. He was treated with pyrimethamine 100 mg/day and sulphadiazine 4 g/day without clinical improvement. A second T2-weighted MRI scan showed confluent high signal intensity in the left centrum semi-ovale, left corona radiata with extension in left internal capsule and corpus callosum without mass effect or significant contrast enhancement. These data supported the clinical diagnosis of PML. The patient died 2 days later. No post-mortem examination was performed.

Patient 50 was a 66-year-old man without known risk factors, diagnosed as HIV-infected in Oct. 1994. He was admitted in Jan. 1995 because of fever and cough. Before this presentation he had no major opportunist infections. He was treated with zidovudine (500 mg/day) plus co-trimoxazole as prophylaxis for TE and *Pneumocystis carinii* pneumonia. His CD4+ lymphocyte count was $< 50/\mu\text{l}$. Radiographs of the chest revealed hilar lymphadenopathy and increased diffuse reticulonodular opacification in both lungs. Examination of an induced sputum specimen showed no *P. carinii*. At this time neurological examination revealed normal mental status, cranial nerves, sensation and strength. The patient was discharged and his condition remained stable for 5 months. In June 1995 the patient developed weakness in his lower right leg and foot and became disoriented and somnolent with impaired co-ordination. A CSF sample was reported as normal. Serology and PCR analysis for *T. gondii* were both negative. CSF was also negative by PCR for HCMV and EBV DNA. A cryptococcal antigen test was negative. A CT scan revealed cerebral atrophy and a single hypodense mass lesion in the left internal capsule with mild contrast enhancement. Based on the presumptive diagnosis of TE, the patient was treated with pyrimethamine 100 mg/day and sulphadiazine 4 g/day for 10 days. He also received therapy for bacterial, fungal and viral infections. His clinical condition deteriorated the following week with a marked worsening of neurological signs and symptoms and he became comatose. A repeat CT scan demonstrated a remarkable expansion of the previously described cerebral lesion with marked mass

effect and contrast enhancement. Three days later the patient died. No post-mortem examination was performed.

Discussion

In this study SV40 sequences were detected in CSF samples from two AIDS patients clinically diagnosed as having PML and a cerebral mass lesion. The CSF from patient 41 with PML exhibited SV40 Tag-N-terminal sequences only. This result may be explained in different ways: either the viral DNA was re-arranged, as reported by others [18, 21], or viral DNA target sequences differed from SV40 wild-type, which was used to design the oligonucleotide PCR primers. Defective SV40 DNA molecules can be detected in infected human cells, even at low multiplicity of infection [39]. Strain variability also exists in clinical isolates [40]. Moreover, it should be noted that different oligonucleotide sets amplify polyomavirus genomic regions with differing efficiencies [23, 41]. Another possibility is that the sample contained only a portion of the SV40 genome. Sample 41 was negative for JCV by PCR analysis, suggesting that JCV sequences were absent. However, JCV detection by PCR in CSF may not always be 100% sensitive. Nevertheless, the detection of SV40 footprints in a CSF sample from a human JCV-negative PML case is intriguing. SV40 was introduced on a large scale into the human population during the years 1955–1963 through polio vaccines contaminated by this viral agent [42]. Many investigations confirm that SV40, although primarily a monkey virus, can infect man [9, 10, 17, 19, 31]. Patient 41 was too young to have received an SV40-contaminated polio vaccine. Little is known of the mode of SV40 transmission in man [9, 10] but the detection of SV40 sequences in peripheral blood cells (PBC) of tumour patients [19] and in PBC [17, 19, 23] and sperm fluids of healthy individuals [17] suggests that blood and sexual transmission may occur. SV40 multiplication in human tissue may be 'helped' by complementing functions of other viral agents, such as JCV, BKV or HIV, or a combination of them, infecting the same hosts. It is worth noting that reciprocal transactivation occurs between HIV and JCV [43], SV40 and JCV [44] and other viral models [45].

The data from the present study suggest that SV40 could be a human pathogen. SV40 induces PML in monkeys and its pathogenicity is more severe in SIV-infected monkeys [34]. Before the introduction of HAART, up to 10% of AIDS patients developed PML [8], a rate higher than that observed in other immunodeficiency states. SV40 may contribute to the high incidence of PML in HIV-infected patients, exhibiting a pathogenic effect in immunocompromised hosts. SV40 sequences have also been detected in hospitalised children [46].

CSF sample 43, from a second case of PML, was positive for JCV-Tag sequences but the regulatory region was not detected. DNA sequence analysis showed 100% homology with the Tag region of JCV Mad-1 strain. The high heterogeneity of the JCV regulatory region observed by several groups in human PML cases may account for the negative PCR data obtained with the oligonucleotides employed in this study [38, 47].

Patient 50 had an intracranial mass lesion unrelated to *T. gondii* infection. Analysis of the CSF from this patient showed the presence of JCV and SV40 sequences. The detection of three different regions of the SV40 genome, i.e., Tag-N- and -C-terminal and VP1 sequences, combined with DNA sequence analyses, established conclusively that authentic SV40 sequences were present in this specimen. DNA sequencing of the JCV Tag coding sequence showed 100% homology with the JCV wild-type Mad-1 strain, whereas the regulatory region exhibited a sequence corresponding to the JCV archetype strain with deletions and point mutations. The JCV regulatory region of sample 50 may have arisen from a crossing-over between JCV archetype and Mad-1 strains. Although many JCV variants can be detected in human specimens [38, 47], this specific alteration of the JCV regulatory sequence has not been reported before.

The putative role of JCV and SV40 polyomaviruses in brain lesions is of interest. Polyomavirus Tag has several biochemical and biological properties: ATPase, helicase, clastogenic and mutagenic activities; it induces cellular and viral DNA replication and it binds tumour suppressor gene products such as p53 and pRb [9]. Although no direct roles for JCV in the onset or progression of human brain tumours were assessed, recent studies found JCV DNA associated with brain neoplasms in the absence of PML [12, 48, 49]. SV40 sequences have been detected in human brain tumours of different histological types and other human neoplasms by several investigators [9]. Although SV40 strains have been isolated from PML patients previously [26], to our knowledge this is the first study reporting SV40 sequences in CSF samples from two AIDS patients with PML and an intracranial mass lesion.

It will be of great interest to determine whether multiple viruses infecting the same human host may act in synergy to increase their pathogenicity.

We thank Professor Salvatore Delia, Director of the Department of Infectious and Tropical Diseases, University of Rome 'La Sapienza' for making available the clinical specimens employed in this investigation. This study was supported in part by grants from Istituto Superiore di Sanità, Progetto AIDS, Roma (M.T. and C.C.), Associazione Italiana per la Ricerca sul Cancro, Milano (M.T.), Ministero dell'Università e Ricerca Scientifica e Tecnologica, Roma (M.T. and C.C.), Fondazione Ferrero, Alba (M.T.), Consiglio Nazionale delle Ricerche, Progetto Finalizzato Biotecnologie 2, Roma (M.T.) and Azienda Ospedaliera Arcispedale Sant'Anna,

Ferrara, Italy (M.T. and C.C.). F.M. and L.I. were supported by fellowships from the Fondazione Cassa di Risparmio di Cento and Associazione Italiana per la Ricerca sul Cancro, respectively.

References

- Nelson JA, Ghazal P, Wiley CA. Role of opportunistic viral infections in AIDS. *AIDS* 1990; **4**: 1–10.
- Case Records of the Massachusetts General Hospital (Case 36-1996). *N Engl J Med* 1996; **335**: 1587–1595.
- Kuchelmeister K, Gullotta F, Bergmann M, Angeli G, Masini T. Progressive multifocal leukoencephalopathy (PML) in the acquired immunodeficiency syndrome (AIDS). A neuropathological autopsy study of 21 cases. *Pathol Res Pract* 1993; **189**: 163–173.
- Kolson DL, Lavi E, González-Scarano F. The effects of human immunodeficiency virus in the central nervous system. *Adv Virus Res* 1998; **50**: 1–47.
- Koenig S, Gendelman HE, Orenstein JM *et al.* Detection of AIDS viruses in macrophages in brain tissue from AIDS patients with encephalopathy. *Science* 1986; **233**: 1089–1093.
- Beral V, Newton R. Overview of the epidemiology of immunodeficiency-associated cancers. *J Natl Cancer Inst Monogr* 1998; **(23)**: 1–6.
- Kieff E. Current perspectives on the molecular pathogenesis of virus-induced cancers in human immunodeficiency virus infection and acquired immunodeficiency syndrome. *J Natl Cancer Inst Monogr* 1998; **(23)**: 7–14.
- Selik RM, Rabkin CS. Cancer death rates associated with human immunodeficiency virus infection in the United States. *J Natl Cancer Inst* 1998; **90**: 1300–1302.
- Barbanti-Brodano G, Martini F, De Mattei M, Lazzarin L, Corallini A, Tognon M. BK and JC human polyomaviruses and simian virus 40: natural history of infection in humans, experimental oncogenicity, and association with human tumors. *Adv Virus Res* 1998; **50**: 69–99.
- Butel JS, Lednicky JA. Cell and molecular biology of simian virus 40: implications for human infections and disease. *J Natl Cancer Inst* 1999; **91**: 119–134.
- Major EO, Amemiya K, Tornatore C, Houff SA, Berger JR. Pathogenesis and molecular biology of progressive multifocal leukoencephalopathy, the JC virus-induced demyelinating disease of the human brain. *Clin Microbiol Rev* 1992; **5**: 49–73.
- Krynska B, Del Valle L, Croul S *et al.* Detection of human neurotropic JC virus DNA sequence and expression of the viral oncogenic protein in pediatric medulloblastomas. *Proc Natl Acad Sci USA* 1999; **96**: 11519–11524.
- Vallbracht A, Löhler J, Gossmann J *et al.* Disseminated BK type polyomavirus infection in an AIDS patient associated with a central nervous system disease. *Am J Pathol* 1993; **143**: 29–39.
- Flaegstad T, Andresen PA, Johnsen JI *et al.* A possible contributory role of BK virus infection in neuroblastoma development. *Cancer Res* 1999; **59**: 1160–1163.
- De Mattei M, Martini F, Corallini A *et al.* High incidence of BK virus large-T-antigen-coding sequences in normal human tissues and tumors of different histotypes. *Int J Cancer* 1995; **61**: 756–760.
- Bergsagel DJ, Finegold MJ, Butel JS, Kupsky WJ, Garcea RL. DNA sequences similar to those of simian virus 40 in ependymomas and choroid plexus tumors of childhood. *N Engl J Med* 1992; **326**: 988–993.
- Martini F, Iaccheri L, Lazzarin L *et al.* SV40 early region and large T antigen in human brain tumors, peripheral blood cells, and sperm fluids from healthy individuals. *Cancer Res* 1996; **56**: 4820–4825.
- Carbone M, Rizzo P, Procopio A *et al.* SV40-like sequences in human bone tumors. *Oncogene* 1996; **13**: 527–535.
- Yamamoto H, Nakayama T, Murakami H *et al.* High incidence of SV40-like sequences detection in tumour and peripheral blood cells of Japanese osteosarcoma patients. *Br J Cancer* 2000; **82**: 1677–1681.
- Carbone M, Fisher S, Powers A, Pass HI, Rizzo P. New molecular and epidemiological issues in mesothelioma: role of SV40. *J Cell Physiol* 1999; **180**: 167–172.
- Pacini F, Vivaldi A, Santoro M *et al.* Simian virus 40-like DNA sequences in human papillary thyroid carcinomas. *Oncogene* 1998; **16**: 665–669.

22. Woloschak M, Yu A, Post KD. Detection of polyomaviral DNA sequences in normal and adenomatous human pituitary tissues using the polymerase chain reaction. *Cancer* 1995; **76**: 490–496.
23. Martini F, Dolcetti R, Gloghini A *et al.* Simian-virus-40 footprints in human lymphoproliferative disorders of HIV– and HIV+ patients. *Int J Cancer* 1998; **78**: 669–674.
24. Brandner G, Burger A, Neumann-Haefelin D, Reinke C, Helwig H. Isolation of simian virus 40 from a newborn child. *J Clin Microbiol* 1977; **5**: 250–252.
25. Scherneck S, Rudolph M, Geissler E *et al.* Isolation of a SV40-like Papovavirus from a human glioblastoma. *Int J Cancer* 1979; **24**: 523–531.
26. Weiner LP, Herndon RM, Narayan O *et al.* Isolation of virus related to SV40 from patients with progressive multifocal leukoencephalopathy. *N Engl J Med* 1972; **286**: 385–390.
27. Scherneck S, Geissler E, Jänisch W, Rudolph M, Vogel F, Zimmermann W. Isolation of a SV40-like virus from a patient with progressive multifocal leukoencephalopathy. *Acta Virol* 1981; **25**: 191–198.
28. Hayashi T, Sumiyoshi A, Tanaka M, Araki S, Minamishima Y. Progressive multifocal leukoencephalopathy. A case report with special reference to SV40 etiology. *Acta Pathol Jpn* 1985; **35**: 173–181.
29. Eizuru Y, Sakihama K, Minamishima Y, Hayashi T, Sumiyoshi A. Re-evaluation of a case of progressive multifocal leukoencephalopathy previously diagnosed as simian virus 40 (SV40) etiology. *Acta Pathol Jpn* 1993; **43**: 327–332.
30. Stoner GL, Ryschkeiwitsch CF. Reappraisal of progressive multifocal leukoencephalopathy due to simian virus 40. *Acta Neuropathol* 1998; **96**: 271–278.
31. Jafar S, Rodriguez-Barradas M, Graham DY, Butel JS. Serological evidence of SV40 infections in HIV-infected and HIV-negative adults. *J Med Virol* 1998; **54**: 276–284.
32. Holmberg CA, Gribble DH, Takemoto KK, Howley PM, Espana C, Osburn BI. Isolation of simian virus 40 from rhesus monkeys (*Macaca mulatta*) with spontaneous progressive multifocal leukoencephalopathy. *J Infect Dis* 1977; **136**: 593–596.
33. Ilyinskii PO, Daniel MD, Horvath CJ, Desrosiers RC. Genetic analysis of simian virus 40 from brains and kidneys of macaque monkeys. *J Virol* 1992; **66**: 6353–6360.
34. Horvath CJ, Simon MA, Bergsagel DJ *et al.* Simian virus 40-induced disease in Rhesus monkeys with simian acquired immunodeficiency syndrome. *Am J Pathol* 1992; **140**: 1431–1440.
35. Simon MA, Ilyinskii PO, Baskin GB, Knight HY, Pauley DR, Lackner AA. Association of simian virus 40 with a central nervous system lesion distinct from progressive multifocal leukoencephalopathy in macaques with AIDS. *Am J Pathol* 1999; **154**: 437–446.
36. Contini C, Fainardi E, Cultrera R *et al.* Advanced laboratory techniques for diagnosing *Toxoplasma gondii* encephalitis in AIDS patients: significance of intrathecal production and comparison with PCR and ECL-western blotting. *J Neuroimmunol* 1998; **92**: 29–37.
37. Lednicky JA, Stewart AR, Jenkins JJ, Finegold MJ, Butel JS. SV40 DNA in human osteosarcomas shows sequence variability among T-antigen genes. *Int J Cancer* 1997; **72**: 791–800.
38. Ault GS. Activity of JC virus archetype and PML-type regulatory regions in glial cells. *J Gen Virol* 1997; **78**: 163–169.
39. O'Neill FJ, Carroll D. Amplification of papovavirus defectives during serial low multiplicity infections. *Virology* 1981; **112**: 800–803.
40. Stewart AR, Lednicky JA, Butel JS. Sequence analyses of human tumor-associated SV40 DNAs and SV40 viral isolates from monkeys and humans. *J NeuroVirol* 1998; **4**: 182–193.
41. Rizzo P, Carbone M, Fisher SG *et al.* Simian virus 40 is present in most United States human mesotheliomas, but it is rarely present in non-Hodgkin's lymphoma. *Chest* 1999; **116**: 470S–473S.
42. Carbone M, Rizzo P, Pass HI. Simian virus 40, poliovaccines and human tumors: a review of recent developments. *Oncogene* 1997; **15**: 1877–1888.
43. Tada H, Rappaport J, Lashgari M, Amini S, Wong-Staal F, Khalili K. Trans-activation of the JC virus late promoter by the tat protein of type 1 human immunodeficiency virus in glial cells. *Proc Natl Acad Sci USA* 1990; **87**: 3479–3483.
44. Hara K, Sugimoto C, Kitamura T, Aoki N, Taguchi F, Yogo Y. Archetype JC virus efficiently replicates in COS-7 cells, simian cells constitutively expressing simian virus 40 T antigen. *J Virol* 1998; **72**: 5335–5342.
45. Gendelman HE, Phelps W, Feigenbaum L *et al.* Trans-activation of the human immunodeficiency virus long terminal repeat sequence by DNA viruses. *Proc Natl Acad Sci USA* 1986; **83**: 9759–9763.
46. Butel JS, Arrington AS, Wong C, Lednicky JA, Finegold MJ. Molecular evidence of simian virus 40 infections in children. *J Infect Dis* 1999; **180**: 884–887.
47. Elsner C, Dörries K. Human polyomavirus JC control region variants in persistently infected CNS and kidney tissue. *J Gen Virol* 1998; **79**: 789–799.
48. Boldorini R, Caldarelli-Stefano R, Monga G *et al.* PCR detection of JC virus DNA in the brain tissue of a 9-year-old child with pleomorphic xanthoastrocytoma. *J NeuroVirol* 1998; **4**: 242–245.
49. Rencic A, Gordon J, Otte J *et al.* Detection of JC virus DNA sequence and expression of the viral oncoprotein, tumor antigen, in brain of immunocompetent patient with oligoastrocytoma. *Proc Natl Acad Sci USA* 1996; **93**: 7352–7357.