

Case Report

A case of bilateral microsporidial keratitis from Bangladesh – infection by an insect parasite from the genus *Nosema*

Alan Curry,¹ Hardeep Singh Mudhar,² Sumedh Dewan,³
Elizabeth U. Canning⁴ and Bart E. Wagner⁵

Correspondence

Alan Curry

Alan.curry@cmmc.nhs.uk

or

dracurry@btinternet.com

¹Electron Microscopy, Clinical Sciences Building, Manchester Royal Infirmary, Manchester M13 9WL, UK

²National Specialist Ophthalmic Pathology Service, Department of Histopathology, E Floor, Royal Hallamshire Hospital, Sheffield S10 2JF, UK

³Cornea Clinic, Chittagong Eye Infirmary, PO Box 729, Pahartali, Chittagong 4000, Bangladesh

⁴Department of Biological Sciences, Imperial College London, Silwood Park Campus, Ascot SL4 7PY, UK

⁵Electron Microscopy Unit, Department of Histopathology, Northern General Hospital, Herries Road, Sheffield S5 7AU, UK

An HIV-negative patient from Bangladesh with bilateral keratitis was found to be infected with a microsporidian parasite belonging to the genus *Nosema*. Significantly, the patient had bathed in a rural pond 7 days prior to the development of ocular symptoms. *Nosema* parasites are common insect parasites and the source of this microsporidial infection was possibly from mosquito larvae developing in the pond in which the patient bathed. The reduced temperature of the human eye and its immune status may have allowed a poikilothermic insect parasite to establish infection in the cornea of a homeothermic human host. This case highlights the opportunistic potential of insect microsporidial parasites to infect immunocompetent humans as well as those who are immunodeficient.

Received 19 March 2007

Accepted 16 May 2007

Introduction

Microsporidia are all tiny unicellular obligately intracellular parasites. Over half of the known microsporidial species are parasites of insects. Few microsporidia infect humans and most infections are enteric and associated with HIV/AIDS. In the early 1990s, several cases of keratoconjunctivitis associated with HIV infection were reported from the USA (Orenstein *et al.*, 1990). Subsequently, there have been several reports of ocular microsporidial infection in healthy, non-HIV-infected individuals (Chan *et al.*, 2003). Sources of ocular infection with microsporidia remain speculative but it has been suggested that the infection could originate from animals and that it is initiated by direct inoculation into eye abrasions (Curry, 1999).

Case report

The patient was a physically fit and well male, living in Bangladesh. Seven days before the onset of keratitis in both eyes, he visited his rural home where he stayed for 3 or 4 days. Significantly, whilst at his rural home he bathed in a local pond. Seven days later, he presented to his local

ophthalmologists with bilateral blurred vision and red eyes. The visual acuities were 6/12 (left and right). Slit lamp examination revealed multiple white spots at an epithelial level, around the corneal periphery of both eyes. No stromal infiltrates were identified. Superficial punctate keratoconjunctivitis was diagnosed, of probable infective aetiology. The referring ophthalmologist performed a corneal scrape from the left eye and fixed the slides in methanol. The methanol-fixed slides were sent to the UK (Sheffield Eye Pathology Laboratory-HSM). The patient was treated with topical steroids and antibiotics with little effect. After detection of the keratitis, the patient was tested for HIV infection, but the result was negative.

One of the slides was stained with a modified Ziehl–Neelsen stain. The corneal scrape on a second slide was processed into TAAB Emix medium hard resin and sectioned for electron microscopy. After staining with uranyl acetate and lead citrate, the sections were examined with either a Philips CM10 or a Philips EM400 electron microscope and images were recorded.

The modified Ziehl–Neelsen-stained scrape showed 3–5 µm pink, non-budding, oval organisms on light microscopy, on

a background of scattered, rather degenerate corneal epithelial cells (Fig. 1).

Transmission electron microscopy showed microsporidial spores and pre-spore stages with reasonable internal detail despite the original fixation in methanol. Groups of spores were located focally in the corneal tissue, but were not arranged in packets or in rows. Spores on average measured about 2.5 μm in length, although some were up to 3.5 μm . The spore wall was made up of a lucent endospore and a two-layered exospore, which was in direct contact with the corneal cell cytoplasm. The spores showed no evidence of being surrounded by an extra membrane, nor was there any evidence of vesiculo-tubular structures at the surface. Division of the prespore (sporoblast) stages appeared to be by binary fission (disporoblastic), with the pairs of sporoblasts becoming separated immediately after division. Internally, the spores showed two nuclei and there was evidence that they were closely apposed as a diplokaryon (Fig. 2). The polar tube had six to seven coils arranged in a single row (Fig. 3). In a few spores, one or two coils of considerably smaller diameter lay inside the five other coils, a condition called anisofily. However, most spores showed the full complement of large diameter coils in a single row and it was concluded that the presence of small diameter coils was a sign of immaturity and that mature spores were isofilar.

Discussion

Although the true prevalence of ocular microsporidial infection is not known, it does seem that it may be relatively common in the Indian/Bangladeshi subcontinent (Vemuganti *et al.*, 2005; Joseph *et al.*, 2006).

The ultrastructural features seen in the microsporidial parasite found in the patient from Bangladesh were: (a) development in direct contact with host cell cytoplasm; (b) diplokaryotic nuclei; and (c) disporoblastic sporogony.

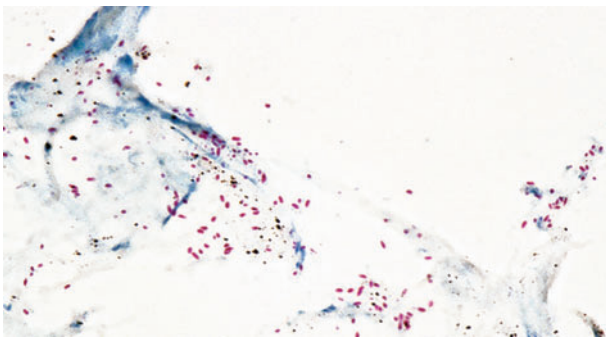


Fig. 1. Ziehl-Neelsen-stained corneal scrape showing microsporidial spores.

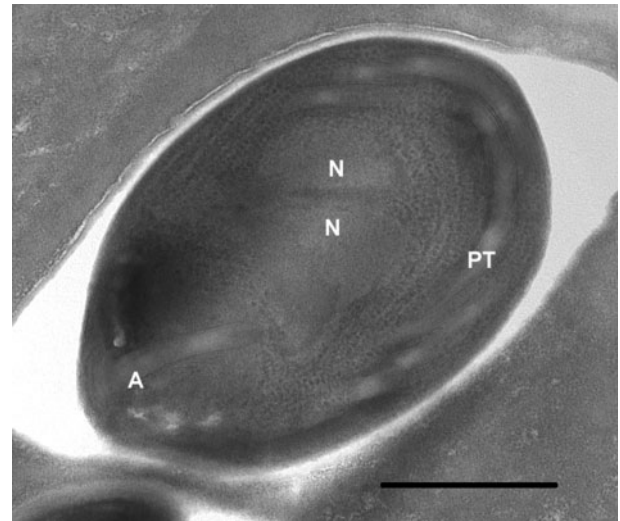


Fig. 2. Interior of a spore showing the polar tube anchoring disc (A), the diplokaryon arrangement of the nuclei (N) and tangentially cut polar tube coils (PT). Bar, 500 nm.

Microsporidian genera that are similar are *Nosema*, *Anncaliia* (*Brachiola*) and *Vittaforma*. The organism detected in this case was not encased by host cell rough endoplasmic reticulum (an external membrane) that is characteristic of *Vittaforma*. Equally there was no evidence of the vesiculo-tubular structures at the surface that are diagnostic of *Anncaliia* (Franzen *et al.*, 2006). On this basis,

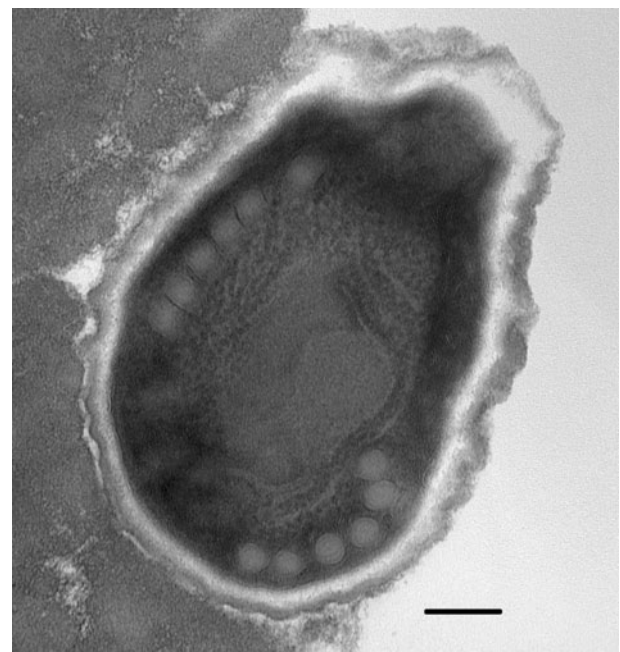


Fig. 3. Mature spore showing six coils of the polar tube. Note that the coils are of equal diameter (isofilar arrangement). Bar, 500 nm.

the parasite is most probably a species within the genus *Nosema*, possibly one of insect origin.

Studies have shown that microsporidial spores can be detected in surface waters (Dowd *et al.*, 1998) and an analysis of risk factors for microsporidiosis showed that swimming in pools was significant (Hutin *et al.*, 1998). It is likely that the infection described in this case occurred whilst bathing in a rural pond in Bangladesh. Such bodies of water will inevitably contain developing insects of various types, for example mosquito larvae. Many microsporidial species are known to infect mosquitoes and other haematophagous insects ('biting flies') and this has led Curry (1999) and Cheney *et al.* (2000) to suggest that these might be the source of some microsporidial infections in humans. The primary hosts of the microsporidian *Nosema algerae* (now *Anncaliia algerae*) are mosquitoes and this organism has been detected in an ocular infection of an immunocompetent human (Visvesvara *et al.*, 1999), showing that this microsporidian can replicate in some human tissues. In the case described here, it is possible that bathing allowed direct contact with microsporidian spores, which germinated and initiated infection into the corneal epithelium. The immune status of the human eye and its lower temperature may also favour opportunistic infection by microsporidia normally adapted to a poikilothermic existence in insects.

Treatment of the keratitis with topical steroids and antibiotics was ineffective, which alerted the patient's local ophthalmologists to consider that the infection was caused by microsporidia. Management of such microsporidial infections is difficult as they can be refractory to medical therapy. However, there are reports of response by using topical fumagillin and oral albendazole (Rauz *et al.*, 2004).

This case highlights the opportunistic potential for insect microsporidia found in ponds to infect immunocompetent humans as well as those with an underlying immunodeficiency.

References

- Chan, C. M. L., Theng, J. T. S., Li, L. & Tan, D. T. H. (2003). Microsporidial keratitis in healthy individuals. *Ophthalmology* **110**, 1420–1425.
- Cheney, S. A., Lafranchi-Tristem, N. J. & Canning, E. U. (2000). Phylogenetic relationships of Pleistophora-like microsporidia based on small subunit ribosomal DNA sequences and implications for the source of *Trachipleistophora hominis* infections. *J Eukaryot Microbiol* **47**, 280–287.
- Curry, A. (1999). Human microsporidial infection and possible animal sources. *Curr Opin Infect Dis* **12**, 473–480.
- Dowd, S. E., Gerba, C. P. & Pepper, I. L. (1998). Confirmation of the human pathogenic microsporidia *Enterocytozoon bienersi*, *Encephalitozoon intestinalis* and *Vittaforma corneae* in water. *Appl Environ Microbiol* **64**, 3332–3335.
- Franzen, C., Nasonova, E. S., Scholmerich, J. & Issi, I. V. (2006). Transfer of the members of the genus *Brachiola* (Microsporidia) to the genus *Anncaliia* based on ultrastructural and molecular data. *J Eukaryot Microbiol* **53**, 26–35.
- Hutin, Y. J., Sombardier, M. N., Liguory, O., Sarfati, C., Derouin, F., Mondai, J. & Monila, J. M. (1998). Risk factors for intestinal microsporidiosis in patients with human immunodeficiency virus infection: a case control study. *J Infect Dis* **178**, 904–907.
- Joseph, J., Sharma, S., Murthy, S. I., Krishna, P. V., Garg, P., Nutheti, R., Kenneth, J. & Balasubramanian, D. (2006). Microsporidial keratitis in India: 16S rRNA gene-based PCR assay for diagnosis and species identification of microsporidia in clinical samples. *Invest Ophthalmol Vis Sci* **47**, 4468–4473.
- Orenstein, J. M., Seedor, J., Friedberg, D. N., Stenson, S. M., Tierno, P. M., Charles, N. C., Meisler, D. M., Lowder, C. Y., McMahon, J. T. & other authors (1990). Microsporidian keratoconjunctivitis in patients with AIDS. *MMWR Morb Mortal Wkly Rep* **39**, 188–189.
- Rauz, S., Tuft, S., Dart, J. K. G., Bonshek, R., Luthert, P. & Curry, A. (2004). Ultrastructural examination of two cases of stromal microsporidial keratitis. *J Med Microbiol* **53**, 775–781.
- Vemuganti, G. K., Garg, P., Sharma, S., Joseph, J., Gopinathan, U. & Singh, S. (2005). Is microsporidial keratitis an emerging cause of stromal keratitis? A case series study. *BMC Ophthalmol* **5**, 19–33.
- Visvesvara, G. S., Belloso, M., Moura, H., Da Silva, A. J., Moura, I. N., Leitch, G. J., Schwartz, D. A., Chevez-Barrios, P., Wallace, S. & other authors (1999). Isolation of *Nosema algerae* from the cornea of an immunocompetent patient. *J Eukaryot Microbiol* **46** (Suppl.), 10S.