

Key words: *K papovavirus/polyoma virus/chronic infection*

Chronic Infection of Nude Mice by Murine K Papovavirus

By JOHN E. GREENLEE†

Department of Neurology, University of Virginia Medical Center, Charlottesville, Virginia 22908, U.S.A.

(Accepted 17 February 1986)

SUMMARY

Nude (nu/nu) mice were inoculated intracranially with $10^{6.5}$ newborn mouse 50% lethal doses of K virus and were studied over a period of 28 weeks using serological methods, virus assay and immunohistological staining for viral antigens. K virus infection of nude mice, although clinically asymptomatic, was slowly progressive despite prompt IgM and IgG antibody response. The highest titres of K virus infectivity were reached in spleens, kidneys and intestines. Vascular endothelial cells represented the major site of viral replication, as has been shown to be the case in immunologically normal mice, with extensive involvement of intestinal capillaries. In addition, however, unlike immunologically normal mice, nude mice inoculated with K virus developed multifocal infection of renal tubular epithelial cells. Nude mice did not develop histologically detectable evidence of central nervous system involvement by K virus, and K virus infection did not result in neoplasia. Infected vascular endothelial cells and renal tubular epithelial cells in animals studied at 16 and 27 weeks after inoculation were grouped in scattered clusters, suggesting local spread of infection. The present study indicates that nude mice with preserved B cell function but impaired T cell-mediated immunity are able to limit systemic dissemination of K virus but are unable to prevent local progression of infection by cell-to-cell spread. K virus is capable of altering its cellular tropism during chronic infection.

INTRODUCTION

K virus is a murine papovavirus which produces a fatal illness in newborn mice and a clinically inapparent infection in older animals. K virus infection of suckling mice is characterized by extensive infection of pulmonary and systemic vascular endothelial cells. Death results from interstitial pneumonia (Fisher & Kilham, 1953; Kilham & Murphy, 1953; Greenlee, 1979; Holt, 1959; Mokhtarian & Shah, 1980). In older suckling mice, K virus produces a protracted infection in which virus and/or viral antigen can be detected in several organs for as long as 4 months (Greenlee, 1981). In adult animals, the virus produces only transient systemic infection with predominant involvement of the intestines (Greenlee, 1981).

Although the pathogenesis of K virus infection in immunologically normal animals has been thoroughly studied, much less is known about K virus infection under conditions of impaired host immunity. Immunosuppression of immunologically naive adult mice with high doses of cyclophosphamide has been shown to convert the self-limited infection usually seen in these animals into a fatal pneumonia identical to that produced by the virus in newborn mice (Mokhtarian & Shah, 1980; J. E. Greenlee, unpublished observations). Immunosuppression of adult mice 8 months after inoculation with K virus at 10 to 14 days of age results in reactivation of latent systemic infection, despite high titres of circulating antiviral antibody (Greenlee & Dodd, 1984). Mokhtarian & Shah (1983) have reported that nude mice inoculated with K virus

† Present address: Neurovirology Research Laboratory (151B), Veterans Administration Medical Center, Salt Lake City, Utah 84148, U.S.A.

develop a non-fatal systemic infection similar in distribution to that produced in immunologically normal adult mice. However, these workers did not ascertain whether K virus infection in nude mice is progressive over time or results in neoplasia. In the present study, nude mice inoculated intracranially with K virus were observed over a period of 6 months to determine whether, in these T cell-deficient animals, K virus produces progressive infection, tumour development or central nervous system pathology similar to that seen in human progressive multifocal leukoencephalopathy (PML).

METHODS

Virus. K virus obtained from the American Type Culture Collection was inoculated intracranially into newborn outbred Swiss mice. A 10% (w/v) extract prepared from pooled lungs, livers, kidneys and spleens of moribund infected animals was used as a crude virus stock (Greenlee, 1979). Purified virus was prepared by banding concentrated suspensions of infected lungs and livers in CsCl with a starting density of 1.33 g/ml with a Beckman SW65 rotor at 50000 r.p.m. for 24 h as previously described (Greenlee, 1979).

Antisera. Antibody to crude virus stock was obtained from adult mice given six weekly intraperitoneal injections of 10^6 newborn mouse 50% lethal doses of K virus (Greenlee, 1979). Antisera to K virus V antigen were prepared by inoculating rabbits at weekly intervals with u.v.-inactivated, gradient-purified virus in Freund's complete adjuvant until their sera produced bright nuclear fluorescence when applied to K virus-infected cells (Greenlee, 1981).

Haemagglutination determinations. Serial twofold dilutions of each sample were prepared in phosphate-buffered saline (PBS). An equal volume of 0.5% sheep erythrocytes was mixed with each dilution, and samples were incubated at 4°C for 4 h.

Studies of antibody response to K virus. Immunofluorescence assays for IgM and IgG (IFA-IgM and IFA-IgG) antibodies to K virus, haemagglutination-inhibition (HI) antibody titrations, and assays of serum neutralizing antibody to K virus were conducted as previously described (Greenlee, 1979, 1981; Greenlee *et al.*, 1982).

Inoculation of animals. Nude (nu/nu) mice at 6 weeks of age were obtained from Charles River Breeding Laboratories (Kingston, N.Y., U.S.A.). Animals were isolated in a laminar flow containment cabinet and were handled using sterile technique. All cages, cage litter, food and drinking water were autoclaved before use. Animals were determined to be free of antibody to K virus or polyoma virus and were inoculated intracranially with 0.02 ml of gradient-purified K virus containing $10^{6.5}$ newborn mouse 50% lethal doses. Animals were sacrificed in groups of four at 2, 4, 8, 12, 16 and 27 weeks after inoculation.

Assay of infected organs. Organs from two animals were pooled, homogenized and sonicated as 10% (w/v) suspensions in Hanks' balanced salt solution. Blood was also pooled. Serial tenfold dilutions of organ suspensions and blood were inoculated onto coverslip cultures of mouse embryo cells as previously described (Greenlee *et al.*, 1982). Coverslips were examined by immunofluorescence staining 14 days after inoculation. The infectivity of the suspension ($TCID_{50}$) was calculated as previously described, using the final dilution that produced positive cells as the endpoint.

Immunohistological studies. Animals at 16 and 27 weeks after inoculation were chosen for more detailed immunohistological study. Animals taken for study 16 weeks after inoculation were perfused with a solution of 96% ethanol and 1% glacial acetic acid in distilled water. Organs from these animals were embedded in glycol methacrylate (JB4; Polysciences) and sectioned at 2 μ m thickness using Ralph knives as previously described (Greenlee & Keeney, 1982). Sections were treated with 0.4% trypsin in Puck's saline with 0.5% $CaCl_2$ for 30 min at 37°C, reacted with rabbit anti-K virus V antigen for 1 h at 37°C and at 4°C overnight, washed twice in PBS, overlaid with fluorescein-conjugated rabbit anti-mouse IgG for 4 h at 37°C, washed in PBS followed by distilled water, and mounted in glycerol (Greenlee & Keeney, 1982). Animals taken for study 27 weeks after inoculation were perfused with 4% paraformaldehyde. Organs from these animals were embedded in paraffin and examined for K virus V antigen using the peroxidase-anti-peroxidase method of Sternberger as modified by Costa *et al.* (1981). Sections of infected organs reacted with normal sera and corresponding organs from uninfected animals served as controls.

RESULTS

Clinical course of K virus infection

Two animals developed hydrocephalus shortly after inoculation and were found to have a sterile ventriculitis. No evidence of K virus infection was present, and intraventricular tumours were not detected. All other animals remained apparently healthy for the duration of the study.

Table 1. Serum antibody response to K virus infection in nude mice*

	Reciprocal of the serum dilution for the following weeks after inoculation					
	2	4	8	13	16	27
IgM-IFA	40	< 10	< 10	ND†	< 10	< 10
IgG-IFA	160	320	320	ND	160	160
Haemagglutination inhibition	20	40	160	ND	20	160
Neutralization	< 20	< 20	20	ND	40	40

* Assays run on pooled sera from two or more animals.

† ND, Not determined.

Table 2. Infectivity content of organs following intracranial inoculation of nude mice with K virus

Weeks after inoculation	Infectivity content* of organs and blood†						
	Lung	Liver	Spleen	Kidney	Intestine	Brain	Blood
2	10 ^{-2.2}	< 10 ^{-1.4} ‡	10 ^{-3.5}	Neg.§	10 ^{-1.8}	< 10 ⁻¹	< 10 ⁻¹
4	10 ^{-2.5}	10 ^{-1.8}	10 ^{-4.4}	< 10 ⁻¹	10 ^{-1.0}	10 ^{-1.8}	Neg.
8	10 ^{-1.7}	10 ^{-1.0}	10 ^{-1.6}	10 ^{-1.6}	10 ^{-2.5}	10 ^{-1.0}	< 10 ⁻¹
13	10 ^{-1.8}	10 ^{-1.6}	10 ^{-4.17}	10 ^{-2.5}	10 ^{-3.5}	10 ^{-1.5}	ND
16	10 ^{-1.8}	10 ^{-3.5}	10 ^{-3.5}	10 ^{-4.4}	10 ^{-6.0}	10 ^{-1.6}	10 ^{-1.25}
27	10 ^{-1.5}	10 ^{-2.2}	10 ^{-3.5}	10 ^{-3.8}	10 ^{-5.0}	< 10 ^{-1.0}	Neg.

* The data are presented as TCID₅₀.

† Each assay was performed on a suspension of organs or on blood pooled from two or more animals.

‡ Specific fluorescence was detected in one of three coverslip cultures inoculated with undiluted material.

§ Neg., Specific fluorescence not detected at 10⁻¹ dilution.

|| ND, Not determined.

Studies of antibody response to K virus

Mice inoculated with K virus exhibited low titres of IgM antibody at week 2 but were without detectable IgM antibody thereafter (Table 1). IgG antibody responses were present at week 2 and titres remained essentially constant at 1:160 to 1:320 throughout the study. HI antibody titres rose more slowly but reached similar levels by week 8. Low titres of neutralizing antibody were first detected 8 weeks after inoculation and persisted at low levels for the duration of the study.

Virus assay

Assay of organs from animals sacrificed 2 weeks after inoculation revealed small amounts of K virus infectivity in lungs, livers, spleens, intestines and brains (Table 2). Amounts of virus remained essentially constant in lungs and brains but gradually increased in livers and spleens. Kidneys were negative for virus at week 2 and contained only trace amounts of virus at week 4 but thereafter contained viral titres approximately equal to those in livers and spleens. Titres of K virus infectivity in intestines rose slowly up to week 13 after inoculation and then increased abruptly between weeks 13 and 16. Trace amounts of virus were detected in blood at weeks 2, 8 and 16 but not at week 4 or week 27.

Antigen localization during chronic K virus infection

Organs from animals sacrificed 16 and 27 weeks after inoculation were prepared for detailed immunohistological analysis. Fluorescent antibody staining of glycol methacrylate sections of lungs from animals sacrificed 16 weeks after inoculation showed that scattered endothelial cells lining pulmonary alveolar walls were positive for K virus V antigen. Infrequently, endothelial cells lining larger vessels and alveolar epithelial cells were also positive. Livers showed scattered

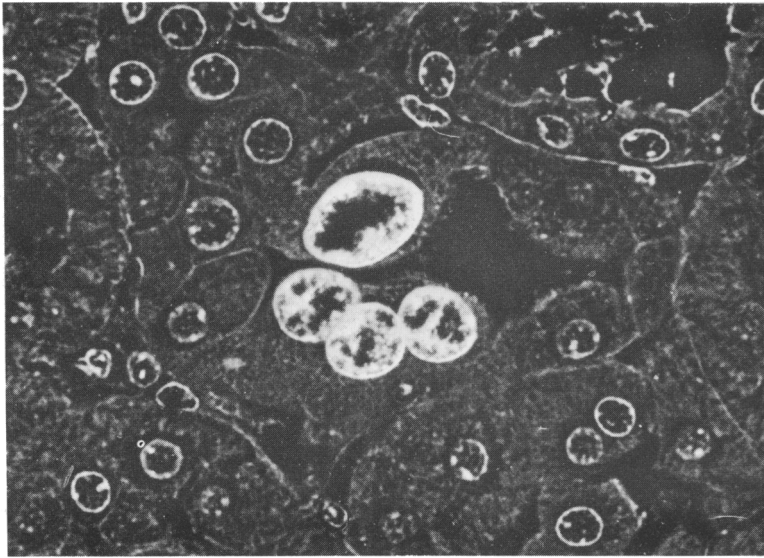


Fig. 1. Section of kidney from nude mouse 16 weeks after intracranial inoculation with K virus, stained using indirect immunofluorescence methods and examined using combined immunofluorescence and phase-contrast microscopy. A cluster of renal tubular cells exhibits bright nuclear fluorescence specific for K virus V antigen. An adjacent section, containing the same cells, was negative for polyoma virus V antigen. Magnification $\times 600$.

cells with nuclear fluorescence along hepatic sinusoids and somewhat larger numbers of cells with granular cytoplasmic fluorescence but unstained nuclei. Spleens contained larger numbers of positive cells than did lungs or livers. Groups of multiple positive cells were frequently found along splenic sinuses. Occasional positive cells were also present in red pulp and splenic follicles. Kidneys contained numerous groups of tubular epithelial cells which exhibited bright nuclear fluorescence specific for K virus V antigen (Fig. 1). Fluorescent antibody stains of these same cells in adjacent sections failed to detect polyoma virus V antigen. Occasional glomerular and interstitial capillary endothelial cells were also positive. Intestines showed extensive staining of vascular endothelial cells within intestinal villi and of occasional nearby cells within the lamina propria. Positive cells were not detected in sections of brains. Examination of animals sacrificed 27 weeks after inoculation revealed a pattern of infection essentially identical to that observed at week 16.

Examination of animals for the presence of tumours

Animals were examined at weekly intervals for development of subcutaneous neoplasms, and careful post mortem examination was conducted on all animals at the time of sacrifice. No tumours were detected by gross or microscopic examination.

DISCUSSION

The present study demonstrates that inoculation of nude mice with K virus results in an infection which is slowly progressive over a period of months and in which the highest titres of infectivity and largest numbers of infected cells are eventually reached in intestines, kidneys and spleens. Virus-infected cells in these chronically infected organs frequently occur in clusters, suggesting extension of infection by cell-to-cell spread. The course of K virus infection in T cell-deficient nude mice is thus markedly different from the transient infection caused by K virus in immunologically normal adult mice and from the fatal pneumonia produced by the virus in adult mice immunosuppressed with cyclophosphamide. Unlike polyoma virus, which causes both productive infection and neoplasia in nude mice (Sebesteny *et al.*, 1980; McCance *et al.*, 1983; Harper *et al.*, 1983; J. E. Greenlee & W. K. Dodd, unpublished observations), K virus produced only chronic infection, without tumour development.

Previous studies of K virus infection in newborn mice have indicated that the virus is acquired in nature by ingestion and that endothelial cells of intestinal villi represent the initial site of viral replication (Greenlee, 1979). These cells are also a major site of viral persistence in older animals surviving acute infection after oral inoculation (Greenlee, 1981). The present study demonstrates that progressive infection of intestinal endothelia may be initiated by blood-borne as well as ingested virus. The high titres of K virus infectivity eventually reached in intestines of nude mice as compared to other organs suggest that spread of infection may be facilitated in these cells, either because of properties peculiar to this group of endothelial cells or because of adaptive changes in the virus itself.

The host mechanisms involved in containment of papovavirus infections are incompletely understood. Papovaviruses JC and BK are ubiquitous agents in human populations and are believed to persist in urinary tissues (Chesters *et al.*, 1983). Impairment of cell-mediated immunity by disease or immunosuppressive therapy is followed by urinary excretion of these viruses in over one-third of patients (Reese *et al.*, 1975; Walker & Padgett, 1983), suggesting an important role for cell-mediated immunity in maintenance of papovavirus latency in man. Urinary shedding of BK and JC virus in immunosuppressed patients is only rarely associated with PML or symptomatic urinary tract infection, however, and it is thus likely that factors in addition to impairment of cell-mediated immunity, such as abnormalities of humoral immunity, may be required for papovaviruses to produce clinical disease. It is of note in this regard that patients with PML have been shown to exhibit a defective antibody response to JC virus (Padgett & Walker, 1983) and that the only four known cases of fatal primary papovavirus infection in human patients (three cases of PML and one case of BK virus-induced interstitial nephritis) have occurred in children with congenital combined immunodeficiency syndromes involving both T and B cell-mediated immune responses (Rosen *et al.*, 1983; Padgett & Walker, 1983).

Studies of K virus infection in mice have shown that recovery from acute infection coincides with the development of circulating antiviral antibody (Greenlee, 1979, 1981; Mokhtarian & Shah, 1980) and that newborn mice can be protected against fatal K virus infection by passive transfer of antiviral antibody and of B cells but not T cells from immune animals (Mokhtarian & Shah, 1980). However, immunosuppression of previously infected mice with cyclophosphamide has been shown to reactivate latent K virus infection despite continued antibody response (Greenlee & Dodd, 1984). These data suggest that containment of acute papovavirus infection is heavily dependent on antiviral antibody but that eventual eradication of productive infection and development of virus latency requires intact T cell function. The present study demonstrates that nude mice inoculated with K virus exhibit prompt IgM and IgG antibody responses, with more gradual development of neutralizing antibodies. This finding is in agreement with previous work by Mokhtarian & Shah (1983), who detected IgM antibodies in nude mice early in acute infection and found that passive transfer of B lymphocytes from infected nude mice prevented the development of fatal K virus pneumonia in newborn mice. In the present study, the antibody response to K virus in nude mice was less vigorous than that seen in immunologically normal animals (Greenlee, 1981; Greenlee & Dodd, 1984) but would appear to have been sufficient to prevent development of clinically apparent illness. However, development of circulating antibody to K virus did not result in clearance of virus from the blood. K virus antigen has been identified in sloughed vascular endothelial cells within vessels (J. E. Greenlee, unpublished observations), and K virus particles have been found within circulating polymorphonuclear leukocytes (Jordan & Doughty, 1969). Persistence of K virus infectivity in the blood of nude mice may thus represent virus sequestered from antibody within cells or cellular debris. Such sequestered virus could provide an additional mechanism for spread of infection after development of circulating antibody. Sequestration of virus within circulating leukocytes or endothelial cell debris may also have accounted, at least in part, for the small amounts of K virus infectivity detected in brains, since cells exhibiting positive immunofluorescence or immunoperoxidase labelling were not found in brains despite an extensive search.

Viral replication during acute K virus infection occurs almost exclusively in vascular endothelial cells, and renal involvement is confined to endothelia of glomerular and

parenchymal capillaries (Fisher & Kilham, 1953; Kilham & Murphy, 1953; Holt, 1959; Greenlee, 1979, 1981; Mokhtarian & Shah, 1980). The finding that nude mice inoculated with K virus develop extensive involvement of renal tubular epithelial cells is thus of interest, since it demonstrates that the cellular tropism of papovaviruses may change during chronic infection. Additional studies are in progress to determine whether inoculation of newborn mice with K virus isolated from kidneys of nude mice with renal tubular involvement produces more extensive renal or central nervous system infection than does wild-type K virus and whether, in nude mice with impaired humoral as well as cell-mediated immunity, this viral isolate produces central nervous system pathology similar to human PML.

The technical assistance of Mr Wendell K. Dodd and Mrs Paula M. Keeney is gratefully acknowledged. The author thanks Dr William G. Stroop for his critical review of this manuscript. This work was supported by Public Health Grant 1 R01 NS 13982 from the National Institute of Neurological and Communicative Disorders and Stroke.

REFERENCES

- CHESTERS, P. M., HERITAGE, J. & MCCANCE, D. J. (1983). Persistence of DNA sequences of BK virus and JC virus in normal human tissues and in diseased tissues. *Journal of Infectious Diseases* **147**, 676-684.
- COSTA, J., HOWLEY, P. M., BOWLING, M. C. & HOWARD, R. (1981). Presence of human papilloma viral antigens in juvenile multiple laryngeal papilloma. *American Journal of Clinical Pathology* **75**, 194-197.
- FISHER, E. R. & KILHAM, L. (1953). Pathology of a pneumotropic virus recovered from C3H mice carrying the Bittner milk agent. *Archives of Pathology* **55**, 14-19.
- GREENLEE, J. E. (1979). Pathogenesis of K virus infection in newborn mice. *Infection and Immunity* **26**, 705-713.
- GREENLEE, J. E. (1981). Effect of host age on experimental K virus infection in mice. *Infection and Immunity* **33**, 297-303.
- GREENLEE, J. E. & DODD, W. K. (1984). Reactivation of persistent papovavirus K infection in immunosuppressed mice. *Journal of Virology* **51**, 425-429.
- GREENLEE, J. E. & KEENEY, P. M. (1982). Immunofluorescent labelling of K-papovavirus antigens in glycol methacrylate embedded material: a method for studying infected cell populations by fluorescence microscopy and histological staining of adjacent sections. *Stain Technology* **57**, 197-205.
- GREENLEE, J. E., DODD, W. K. & OSTER-GRANITE, M. L. (1982). An *in vitro* assay for K-papovavirus of mice. *Journal of Virological Methods* **4**, 139-146.
- HARPER, J. S., III, DAWWE, C. J., TRAPP, B. D., MCKEEVER, P. E., COLLINS, M., WOYCIECHOWSKA, J. L., MADDEN, D. L. & SEVER, J. L. (1983). Paralysis in nude mice caused by polyomavirus-induced vertebral tumors. In *Polyomaviruses and Human Neurological Diseases*, pp. 359-367. Edited by J. L. Sever & D. L. Madden. New York: Alan R. Liss.
- HOLT, D. (1959). Presence of K-virus in wild mice in Australia. *Australian Journal of Experimental Biology* **37**, 183-192.
- JORDAN, S. W. & DOUGHTY, W. E. (1969). Ultrastructural pathology of murine pneumonitis caused by K-papovavirus. *Experimental and Molecular Pathology* **11**, 1-7.
- KILHAM, L. & MURPHY, H. W. (1953). A pneumotropic virus isolated from C3H mice carrying the Bittner milk agent. *Proceedings of the Society for Experimental Biology and Medicine* **82**, 133-137.
- MCCANCE, D. J., SEBESTENY, A., GRIFFIN, B. E., BALKWILL, F., TILLY, R. & GREGSON, N. A. (1983). A paralytic disease of nude mice associated with polyoma virus infection. *Journal of General Virology* **64**, 57-67.
- MOKHTARIAN, F. & SHAH, K. V. (1980). Role of antibody response in recovery from K-papovavirus infection in mice. *Infection and Immunity* **29**, 1169-1179.
- MOKHTARIAN, F. & SHAH, K. V. (1983). Pathogenesis of K-papovavirus infection in athymic nude mice. *Infection and Immunity* **41**, 434-436.
- PADGETT, B. L. & WALKER, D. L. (1983). Virologic and serologic studies of progressive multifocal leukoencephalopathy. In *Polyomaviruses and Human Neurological Diseases*, pp. 107-117. Edited by J. L. Sever & D. L. Madden. New York: Alan R. Liss.
- REESE, J. M., REISSIG, M., DANIEL, R. W. & SHAH, K. V. (1975). Occurrence of BK virus and BK virus-specific antibodies in the urine of patients receiving chemotherapy for malignancy. *Infection and Immunity* **11**, 1375-1381.
- ROSEN, S., HARMON, W., KRENSKY, A. M., EDELSON, P. J., PADGETT, B. L., GRINNELL, B. W., RUBINO, M. J. & WALKER, D. L. (1983). Tubulo-interstitial nephritis associated with polyomavirus (BK type) infection. *New England Journal of Medicine* **308**, 1192-1196.
- SEBESTENY, A., TILLY, R., BALKWILL, F. & TREVAN, D. (1980). Demyelination and wasting associated with polyomavirus infection in nude (nu/nu) mice. *Laboratory Animals* **14**, 337-345.
- WALKER, D. L. & PADGETT, B. L. (1983). The epidemiology of human polyomaviruses. In *Polyomaviruses and Human Neurological Diseases*, pp. 99-106. Edited by J. L. Sever & D. L. Madden. New York: Alan R. Liss.

(Received 3 September 1985)